

# Interventional Radiology

## 介入性放射学

Presented by:

KM Au-Yeung

歐陽啓明

Department of Diagnostic and Interventional Radiology

Hong Kong Sanatorium & Hospital

養和醫院

# Diagnostic Radiology

Use different method:

- X-Ray— CXR, AXR, Bone, mammogram
- Ultrasound scan—HBS, OBS, breast, Doppler scan
- CT scan-- Lung, abdomen, pelvis, bone
- MR scan—Neuroradiology, MSK, breast
- PET scan--Oncology

# Interventional Radiology (IR)

Uses Minimal Invasive or Non-invasive  
Techniques under Image Guidance for

- Diagnosis
- Treatment

# Interventional Procedure

- X-ray guidance
- Ultrasound guidance
- CT guidance
- MRI guidance

# Interventional Procedure

Before the procedure:

Check clotting profile including APTT, PT, INR,  
Platelet count.

Obtain informed consent

Procedure:

Local Anaesthetics

MAC

GA

# Interventional procedure

## I) Vascular Procedure

- Stenting
- Embolization
- Miscellaneous

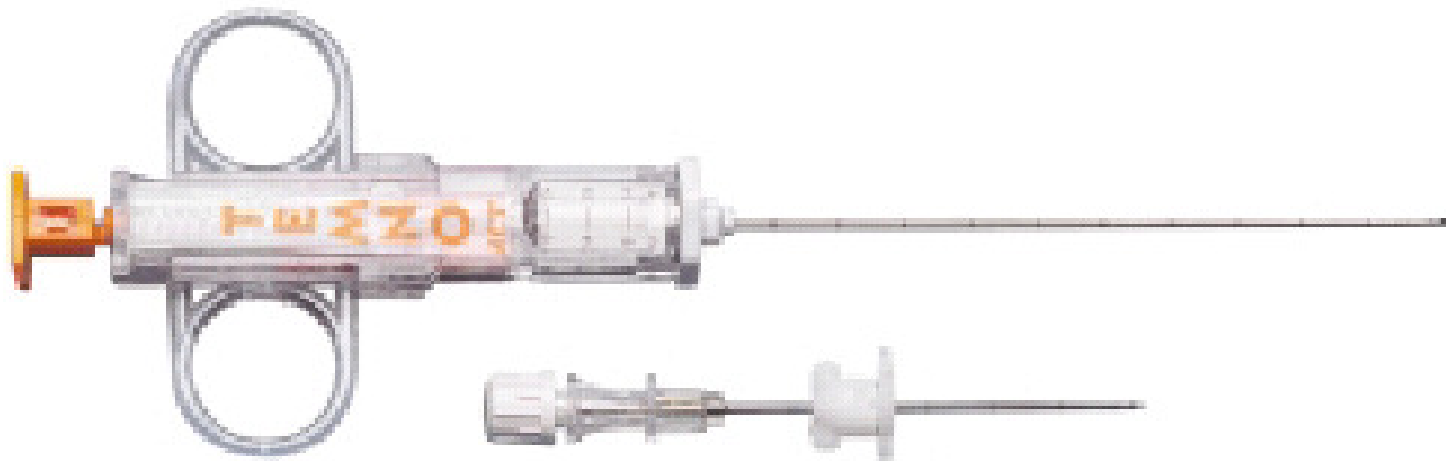
## II) Non-Vascular Procedure

- Biopsy & needle localisation
- Tubes and Drains insertion
- Miscellaneous

# Non-vascular IR Procedure:

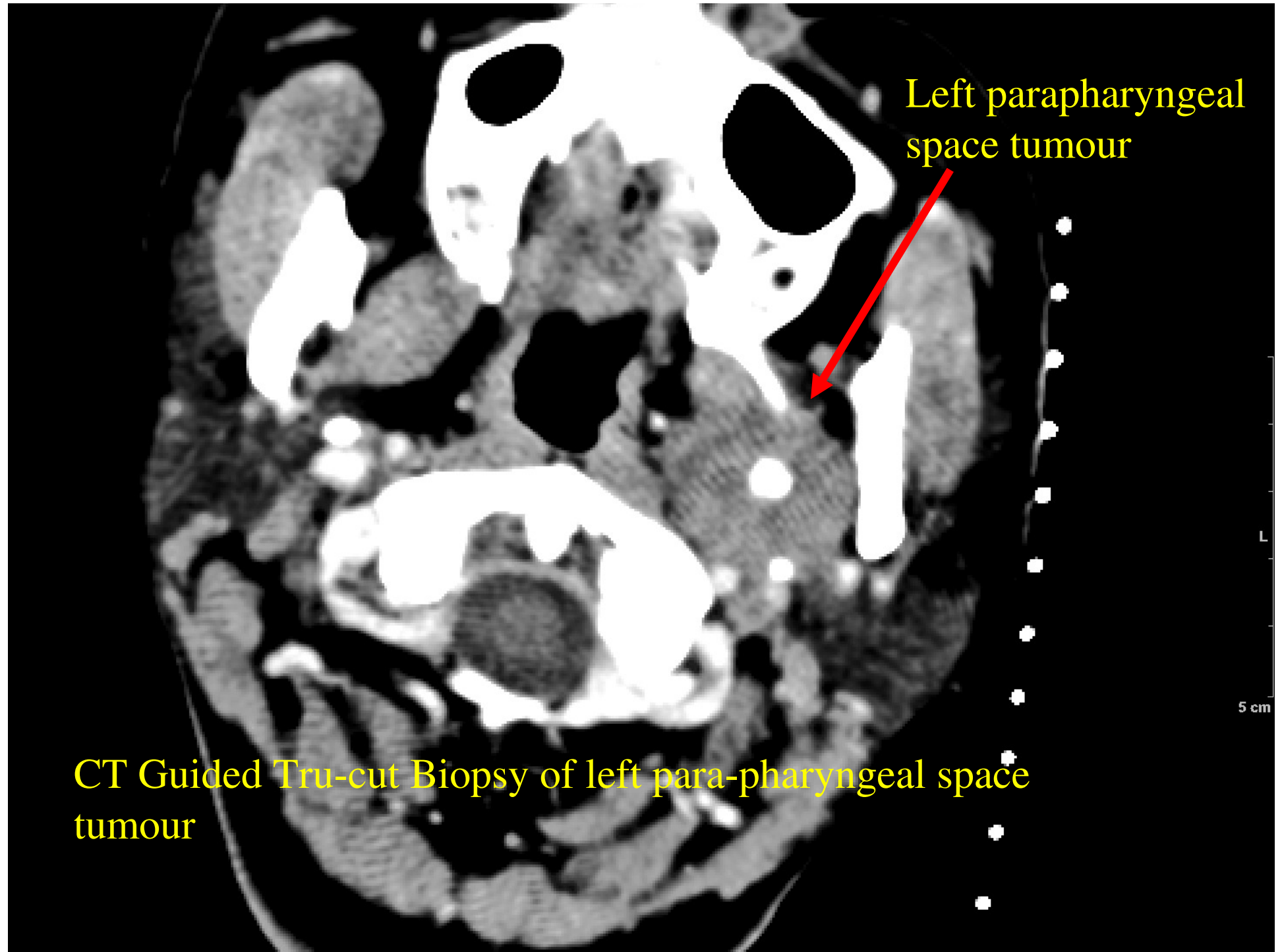
- 1) Head & neck: Biopsy
- 2) Liver : Biopsy, PTBD/PTC, Stenting, abscess drainage
- 2) Kidney : Biopsy, PCN, Stenting
- 3) Lung : Biopsy, Pleural effusion tapping or drainage
- 4) Breast : Biopsy
- 5) Prostate : Biopsy
- 6) Uterus : Focus US

# Tru-cut Biopsy Co-axial Needle



# Head and Neck Tumour OR Lymph Node Biopsy

CT OR US guided Biopsy

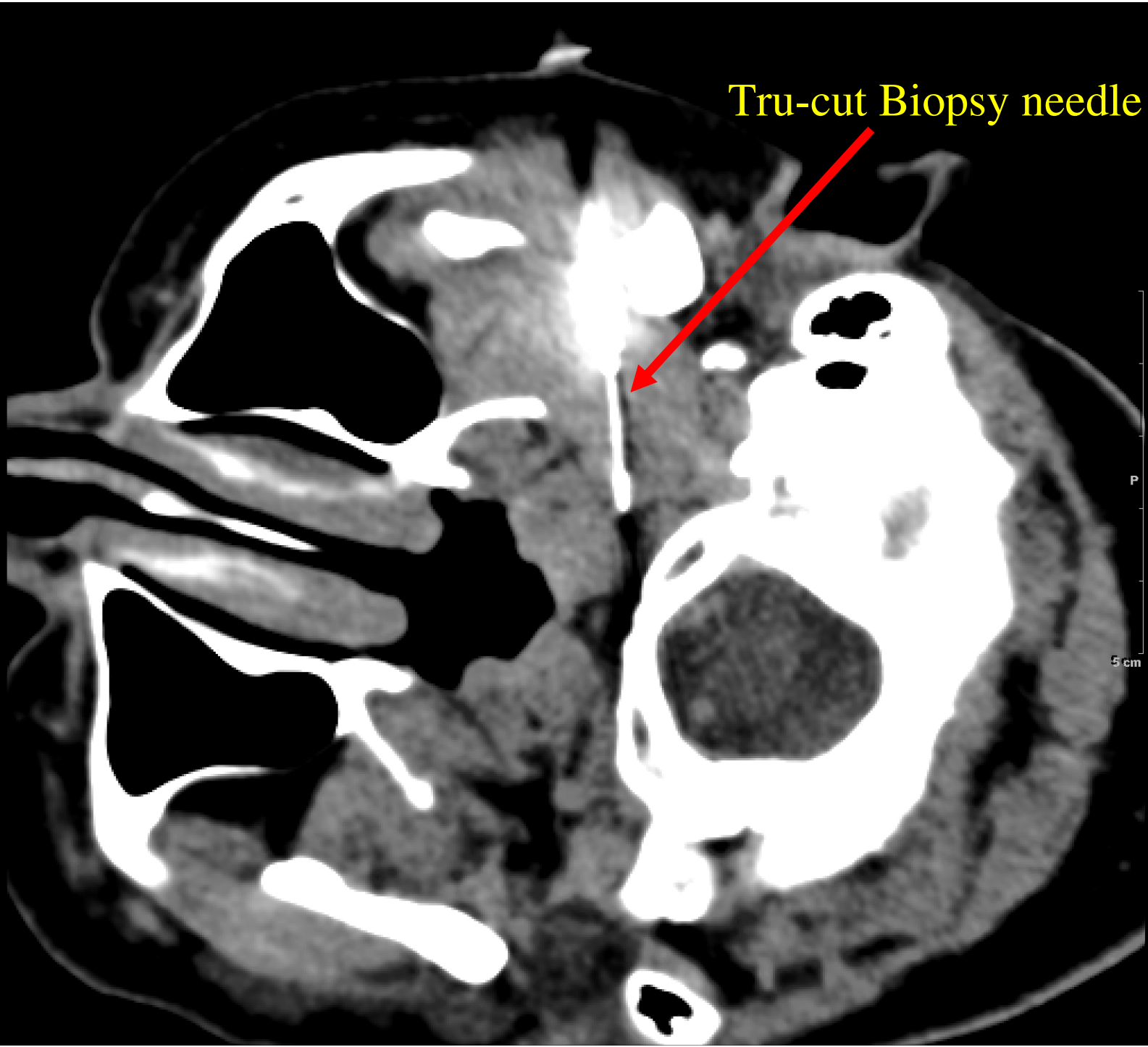
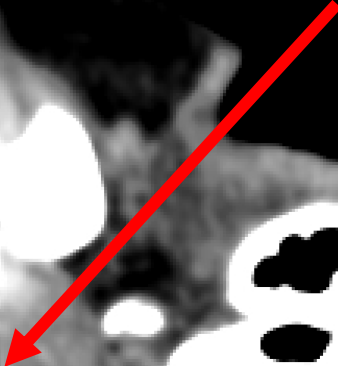


Left parapharyngeal space tumour

CT Guided Tru-cut Biopsy of left para-pharyngeal space tumour

5 cm

Tru-cut Biopsy needle



# Lung Tumour

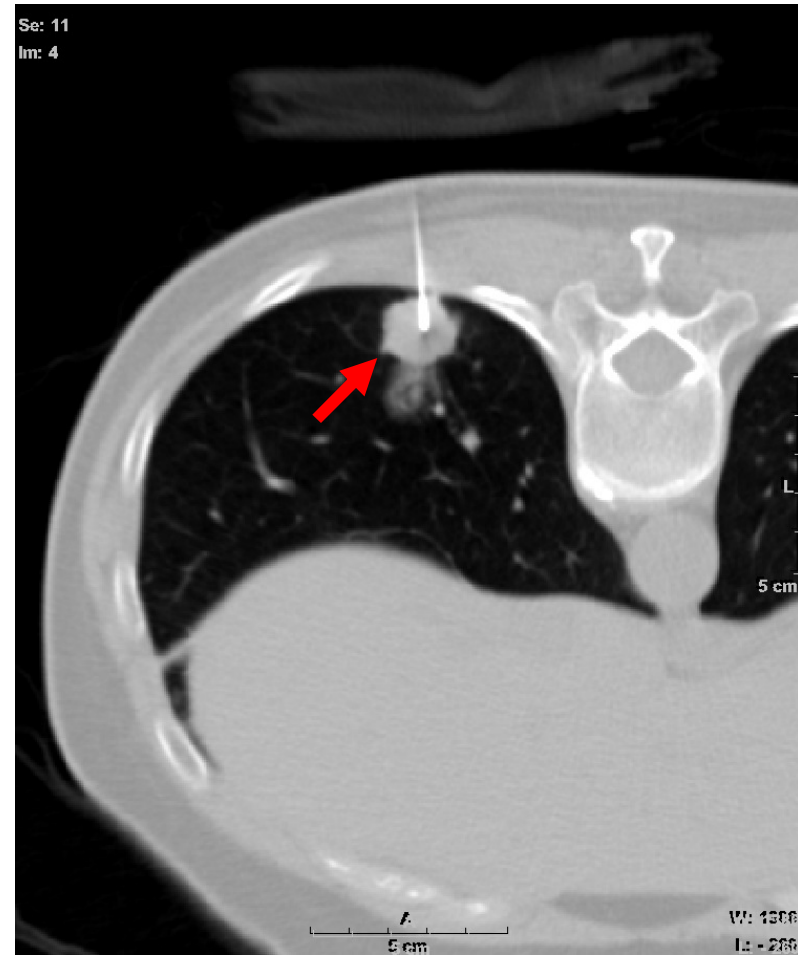
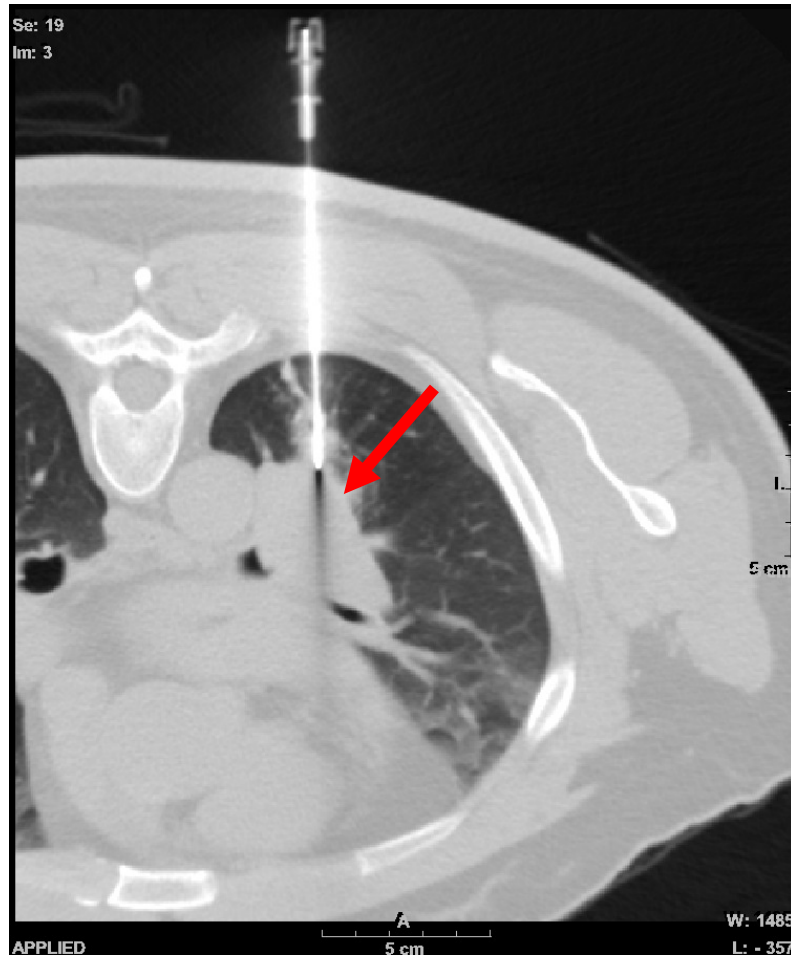
CT guided biopsy & needle localization

Pleural Effusion/


Pneumothorax

CT/US Guided tapping or drainage

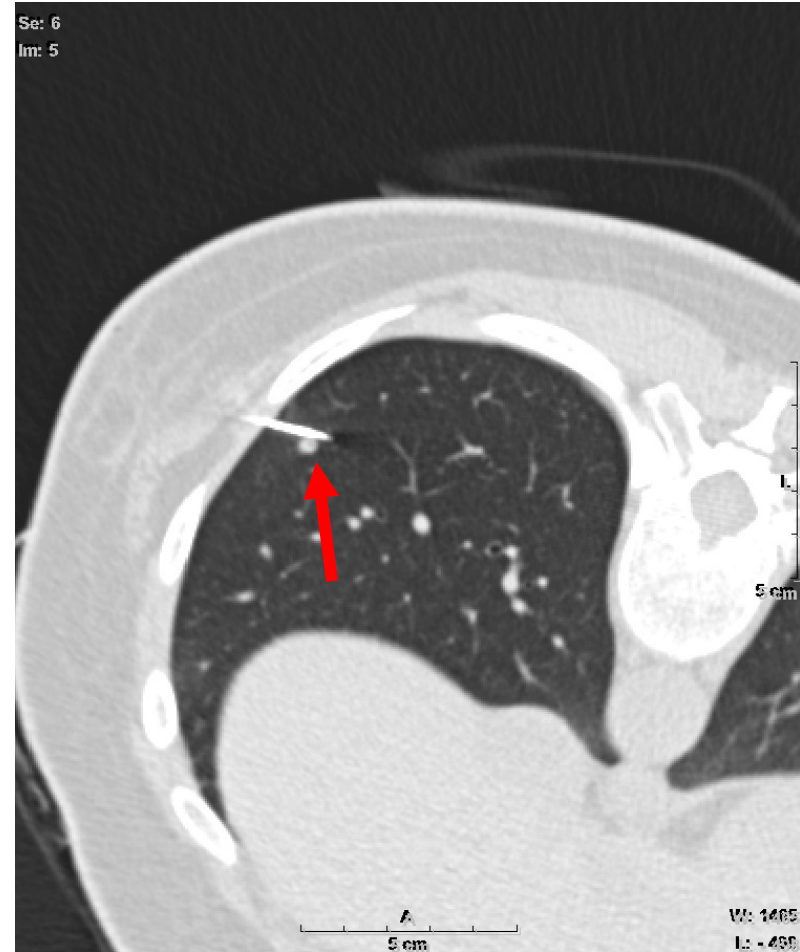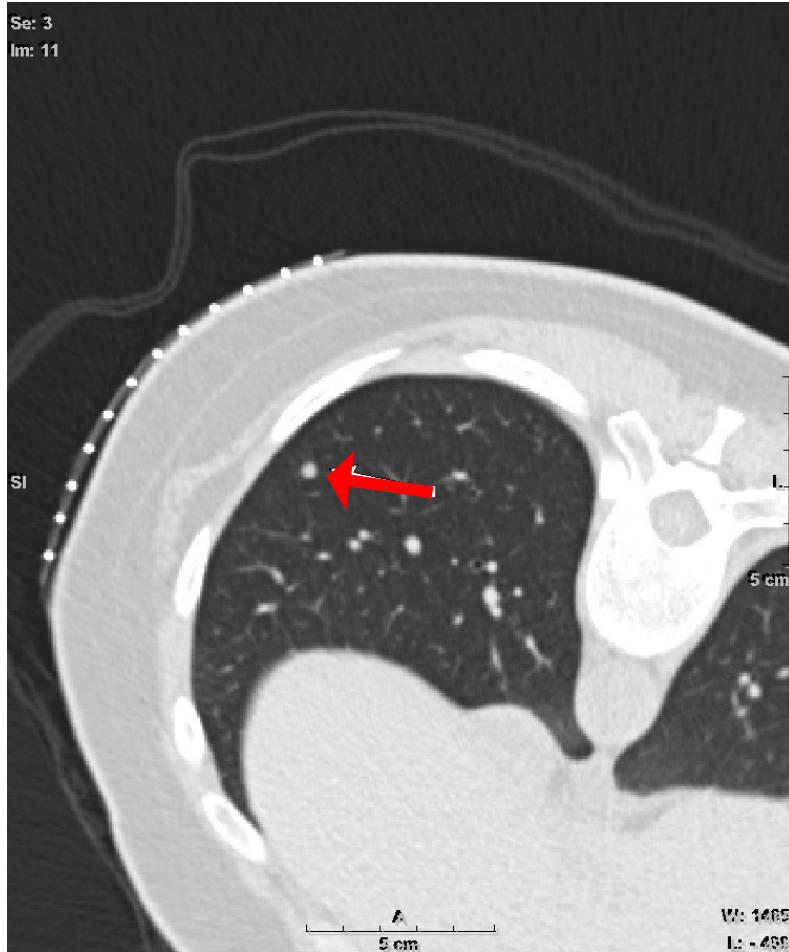# CT guided lung lesion biopsy



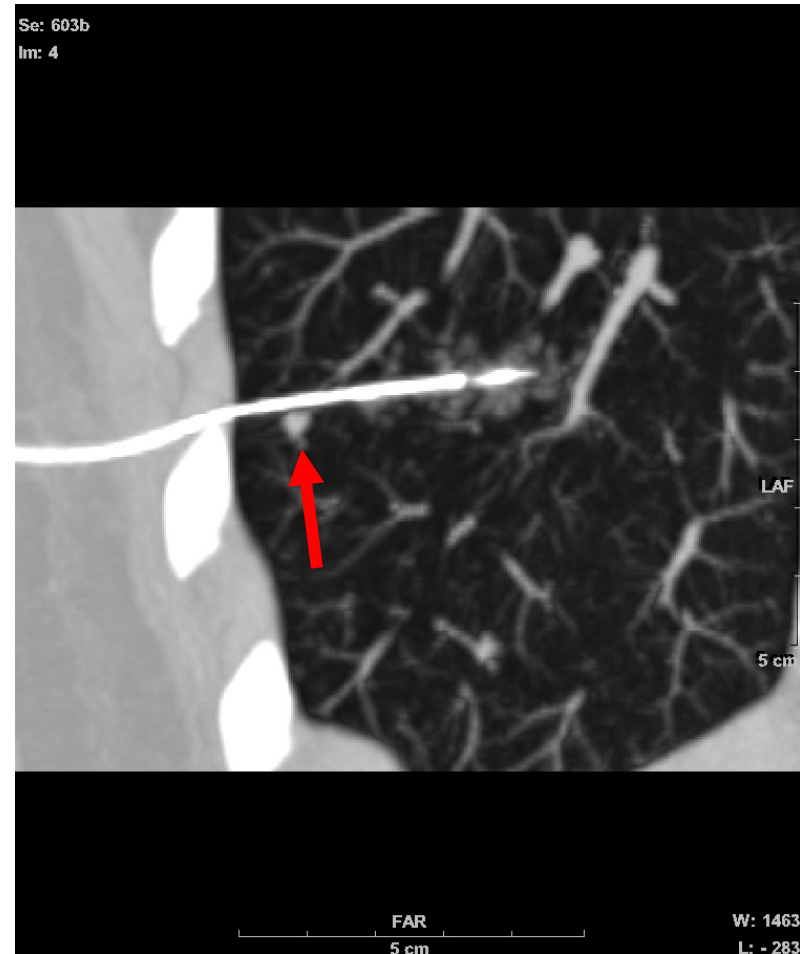
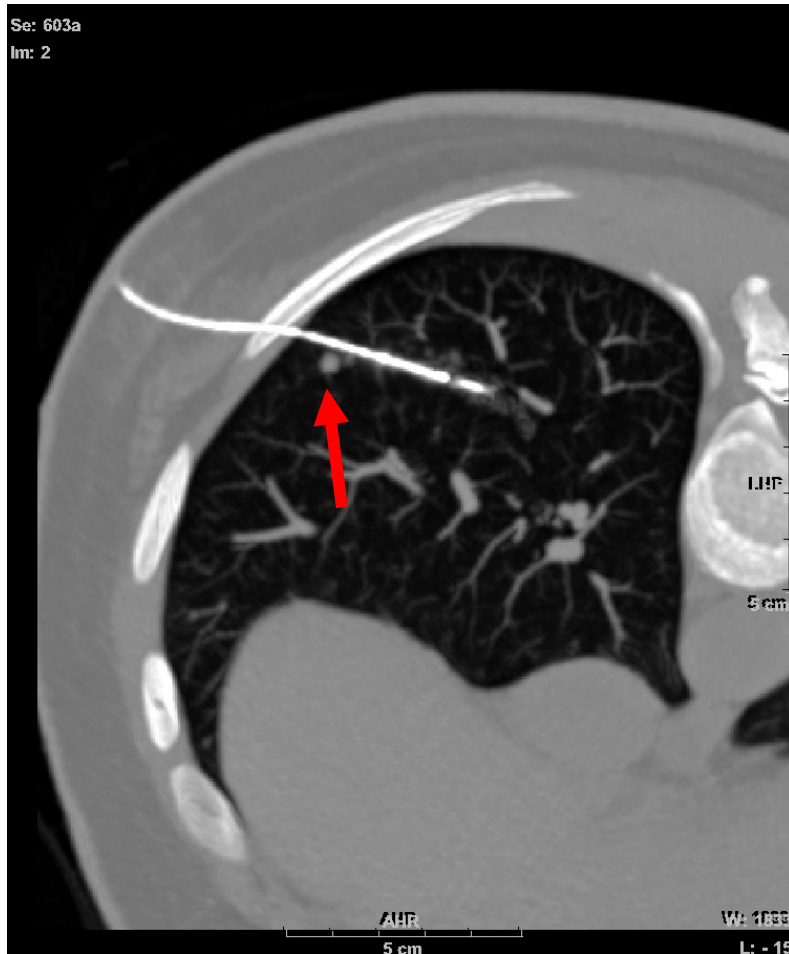# CT guided needle localization of small lung nodule



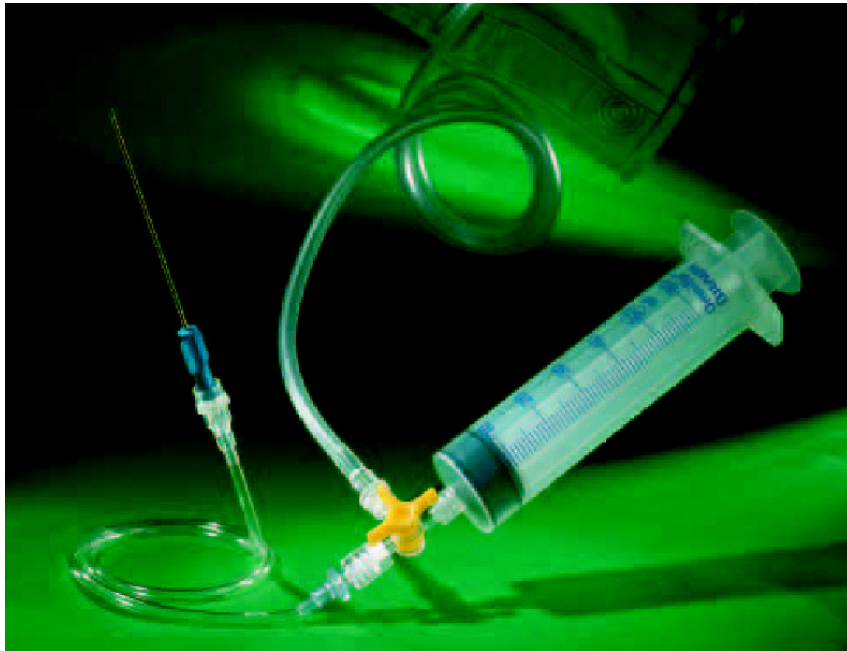# CT guided needle localization of small lung nodule



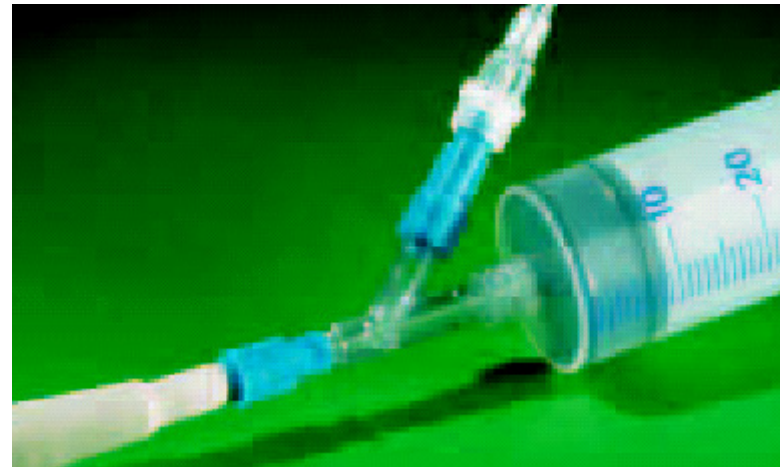# CT guided needle localization of small lung nodule



# Imaging guided thoracic drainage procedures

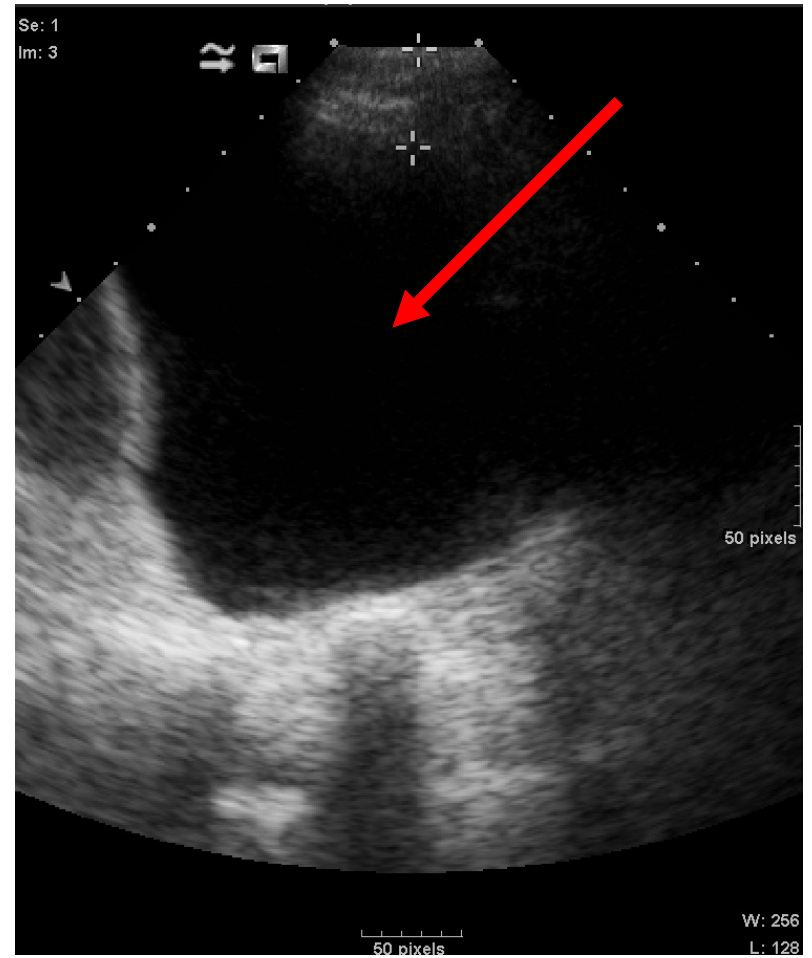
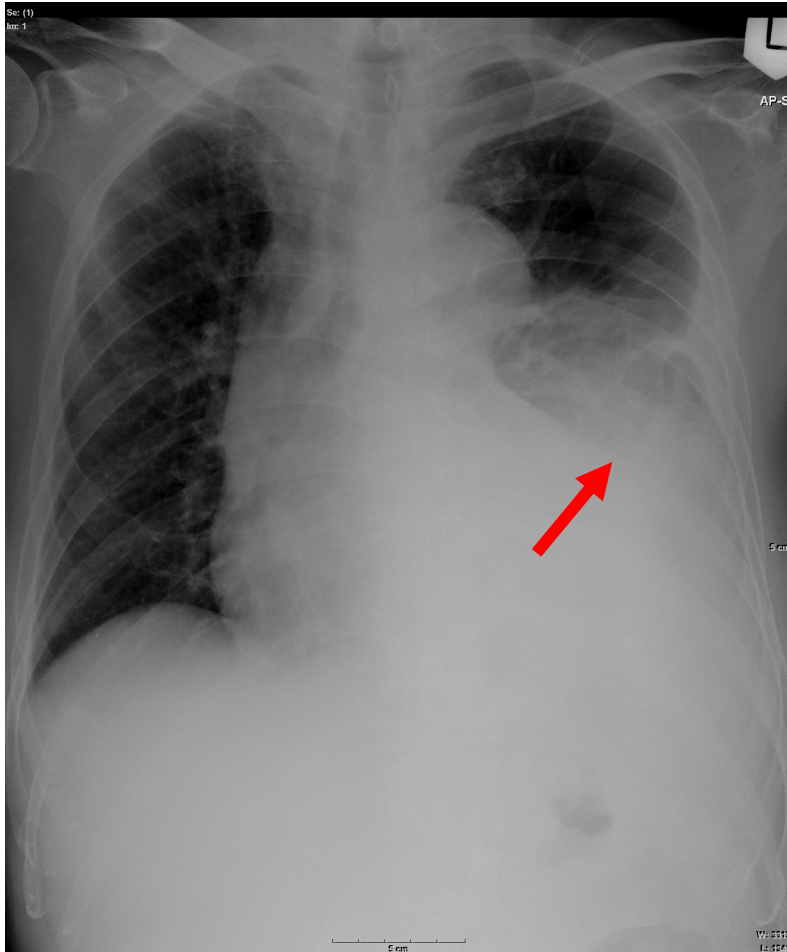


3-Way connector

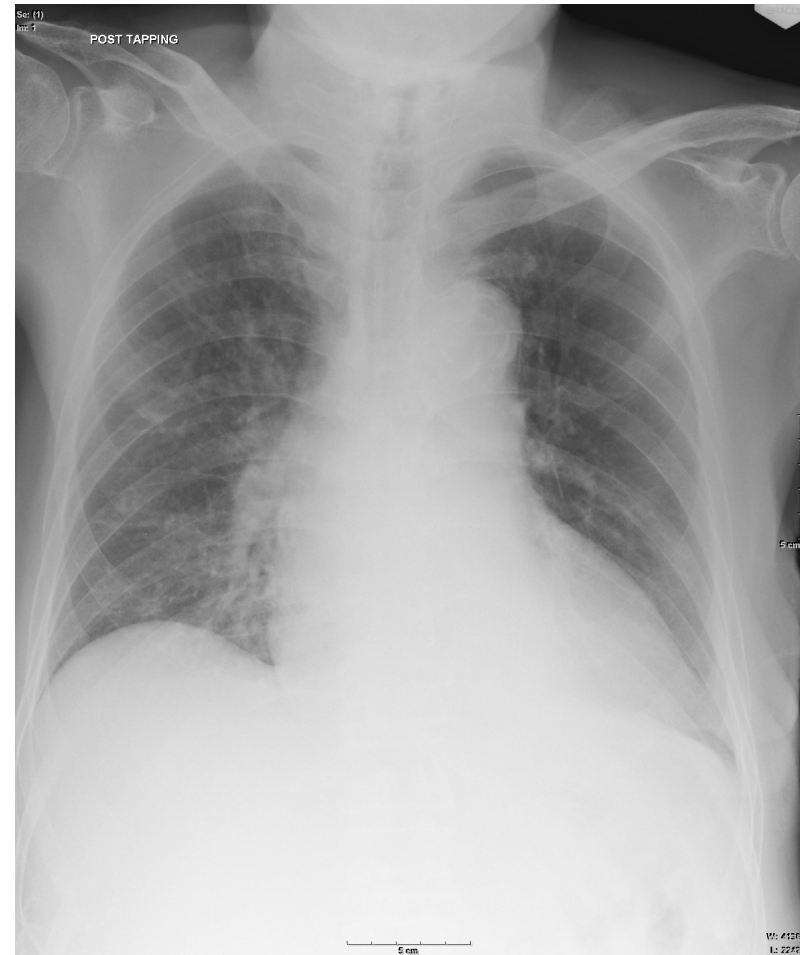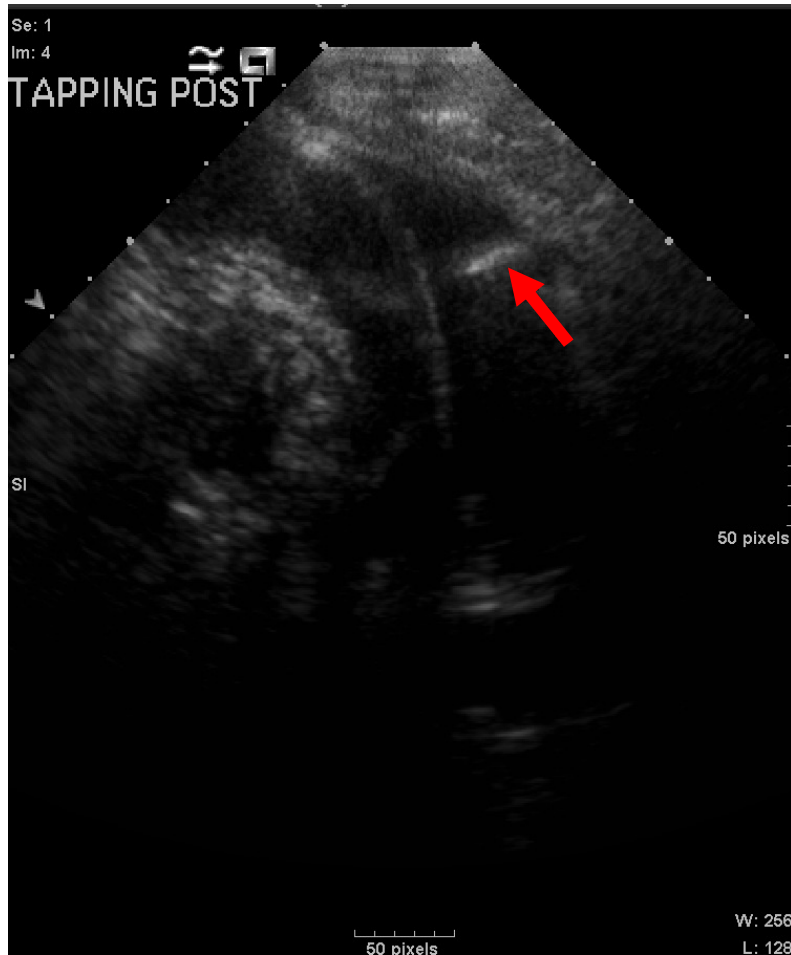


Pleurofix

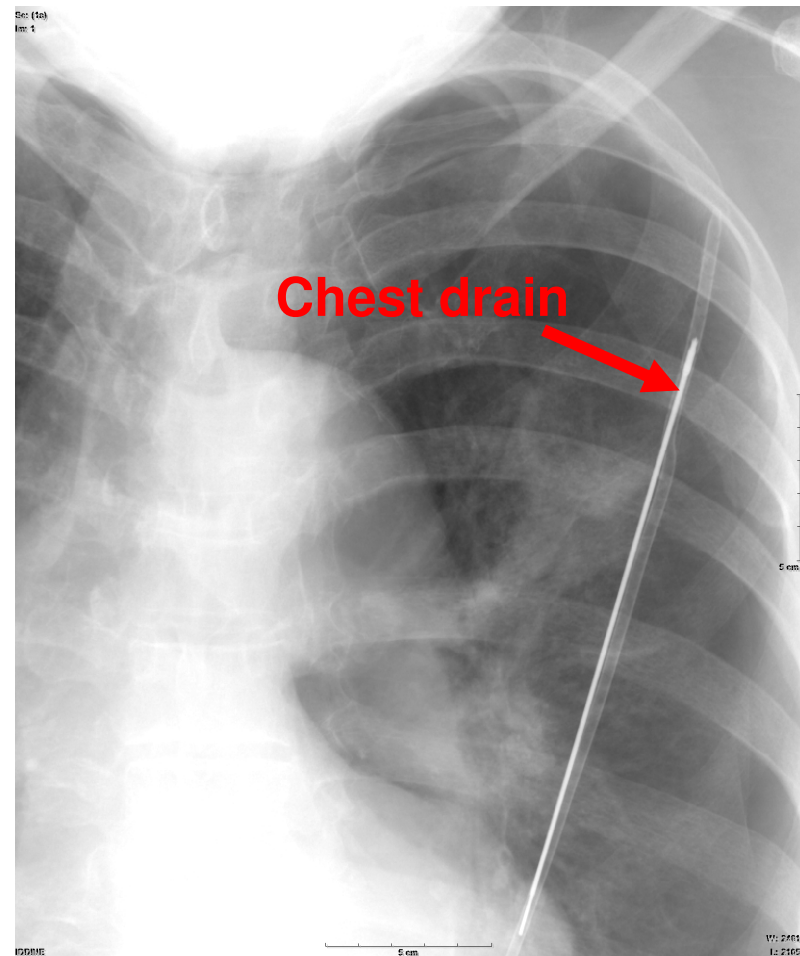
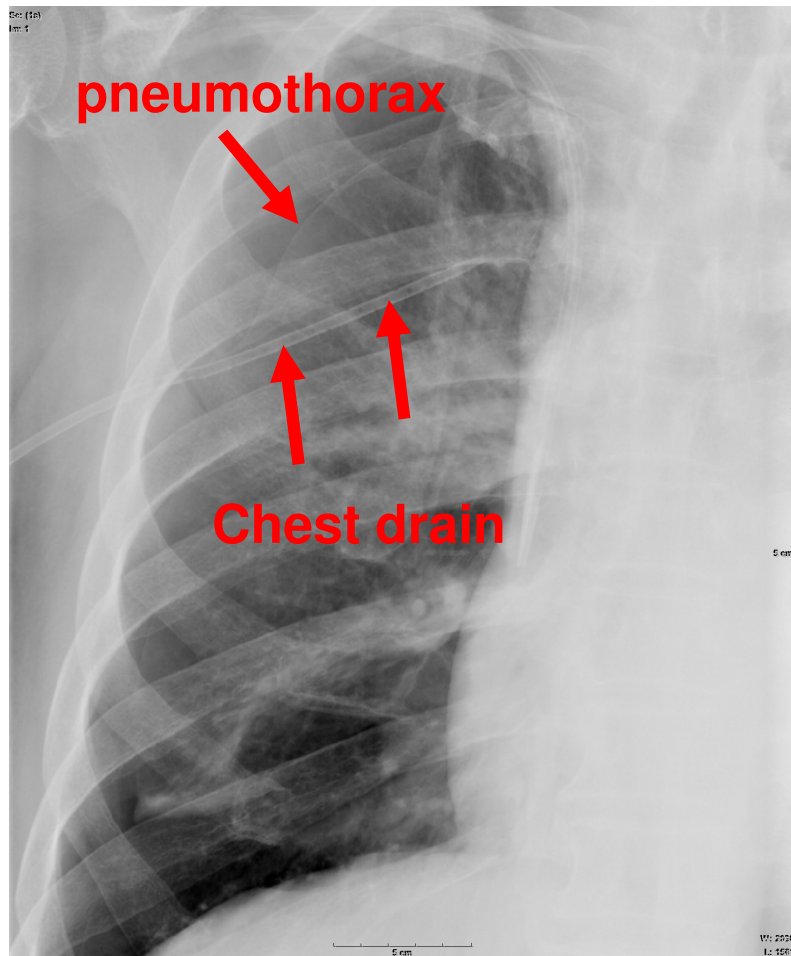
# Pleural effusion



# Pleural effusion



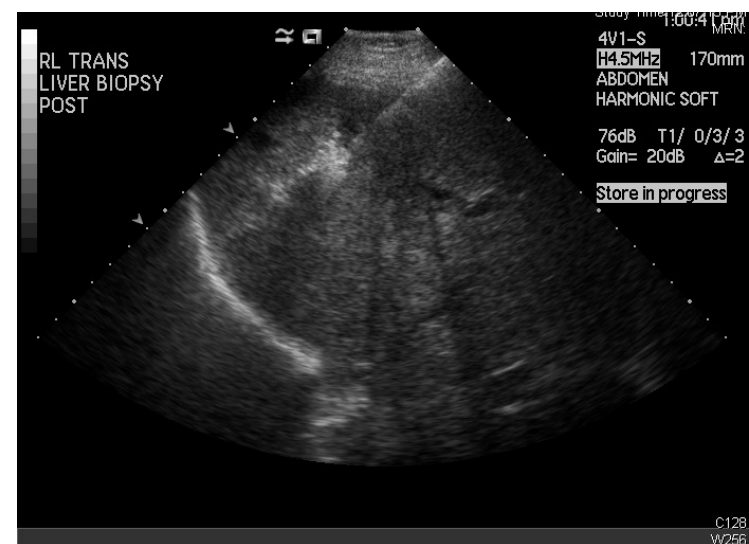
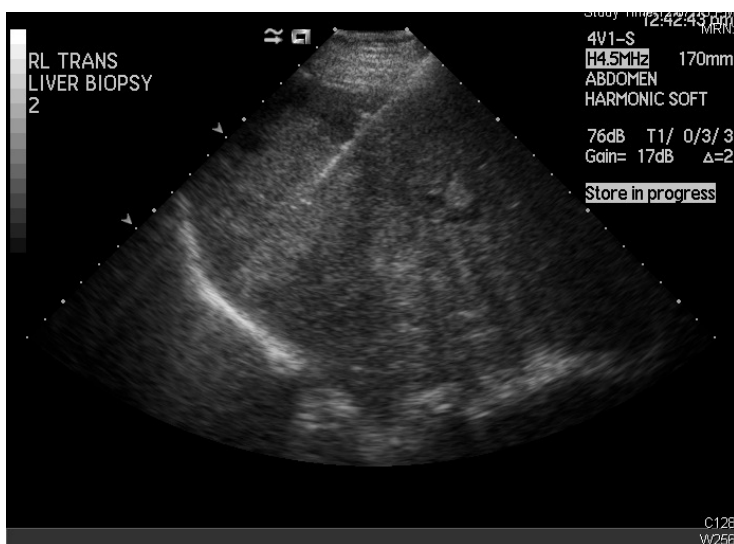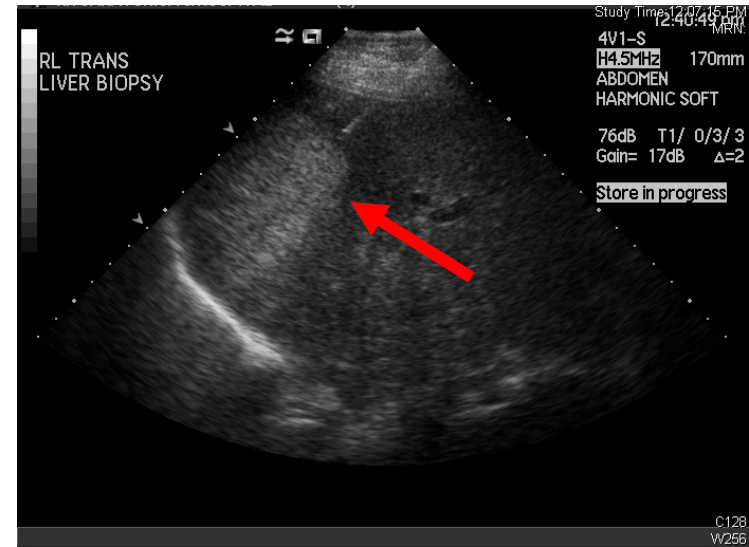
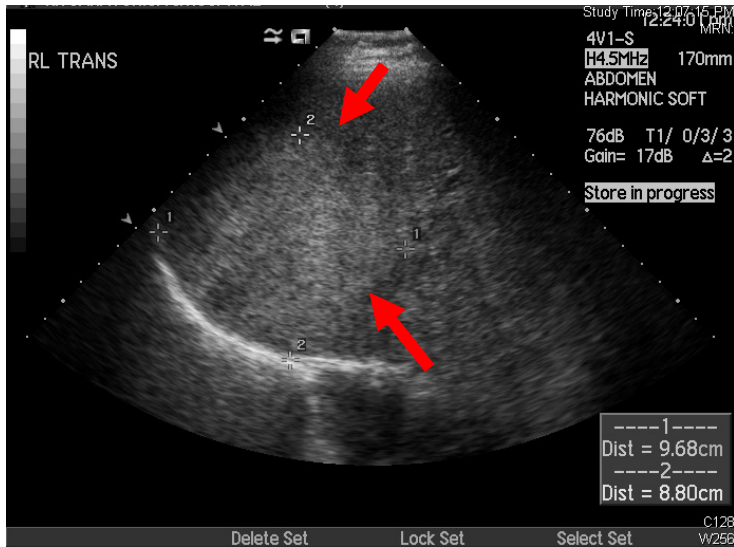
# Pneumothorax



# Liver, Biliary system Procedure

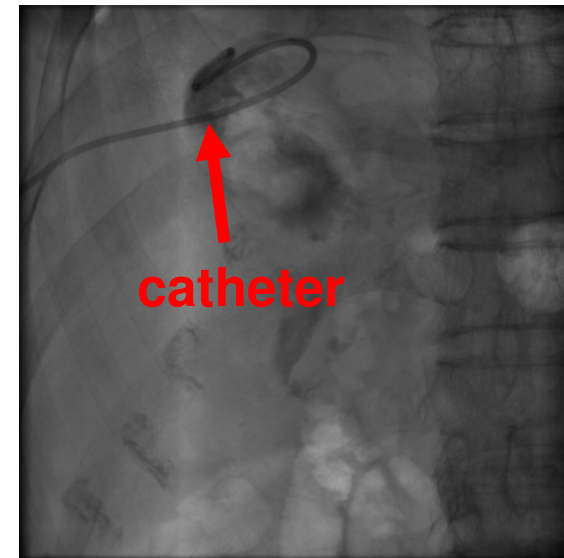
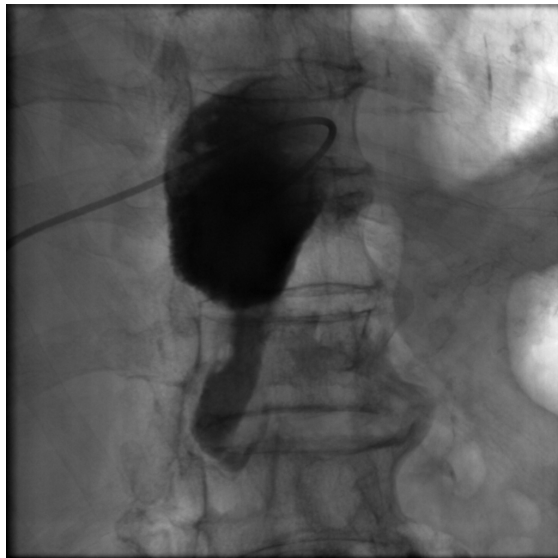
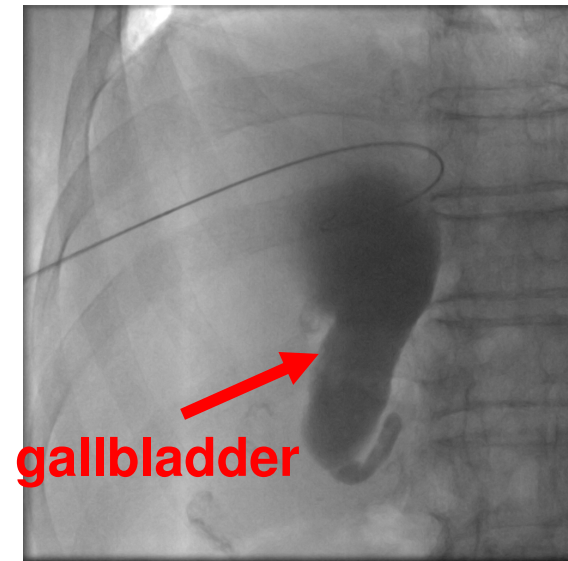
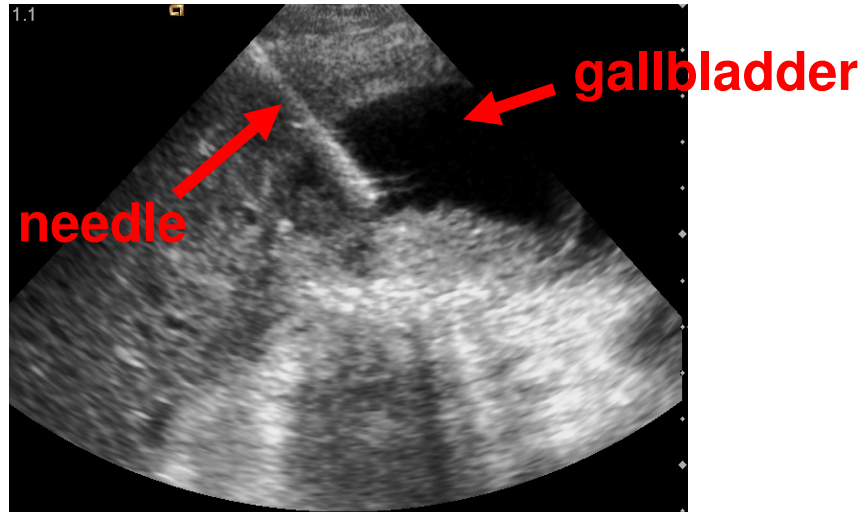
- 1) Biopsy
- 2) Biliary drainage, including PTBD and cholecystostomy
- 3) Biliary stenting

# Ultrasound guided liver lesion biopsy

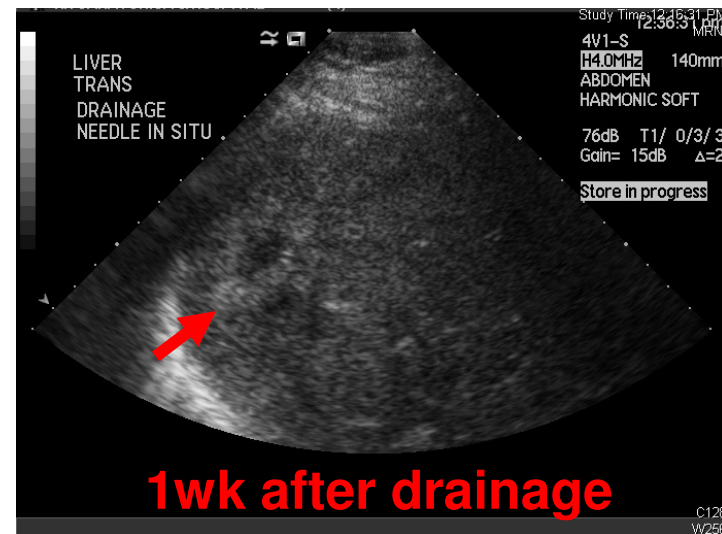
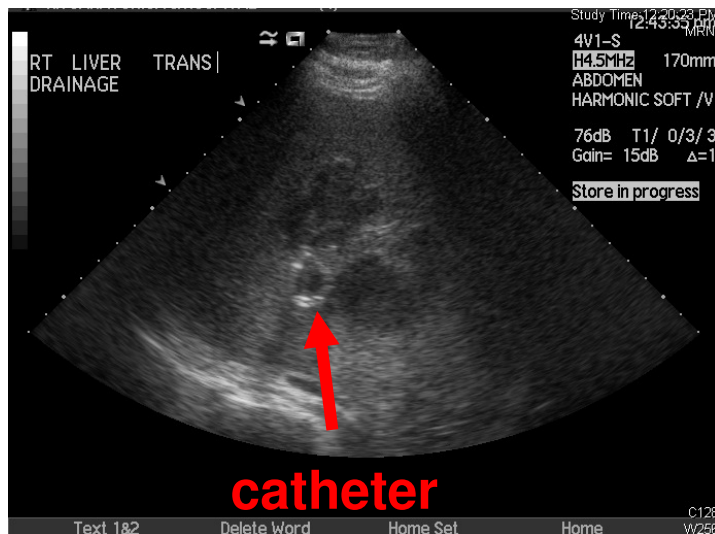
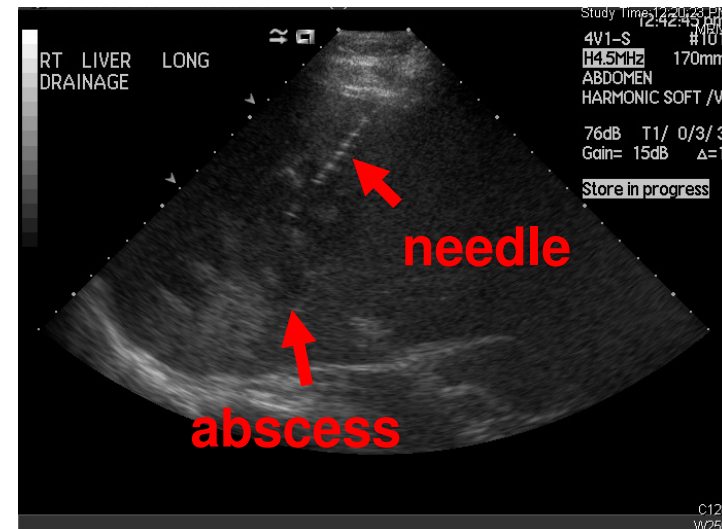
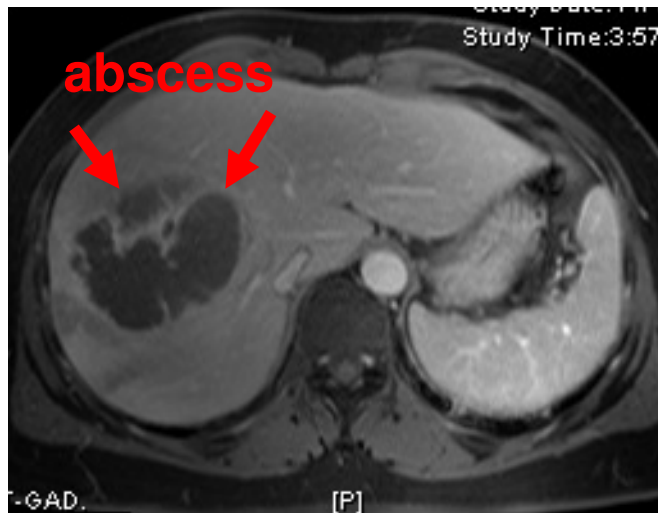


# Percutaneous cholecystostomy

## 膽囊造口術

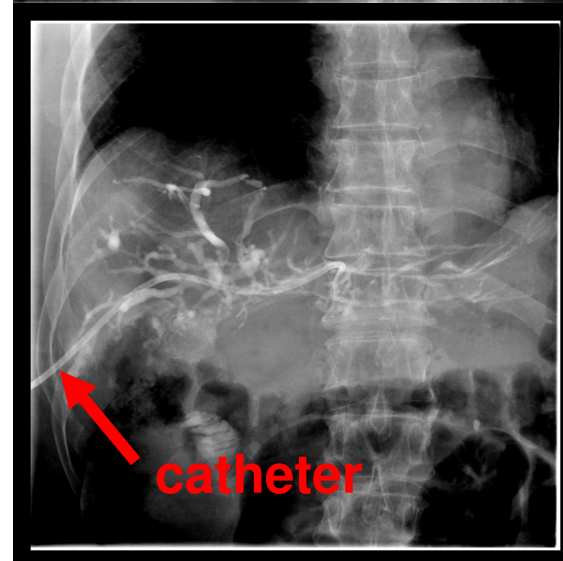
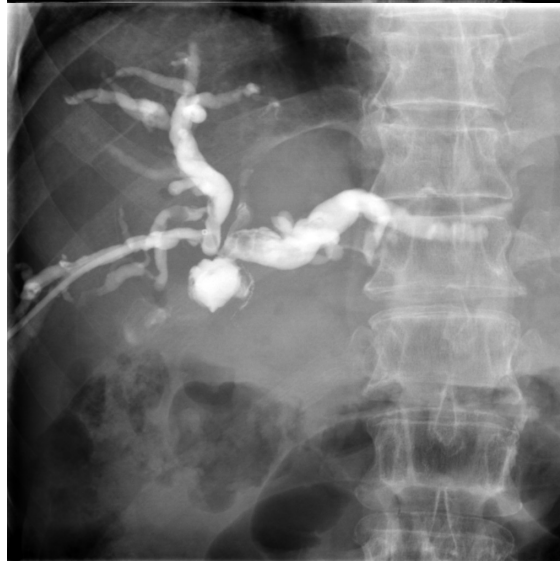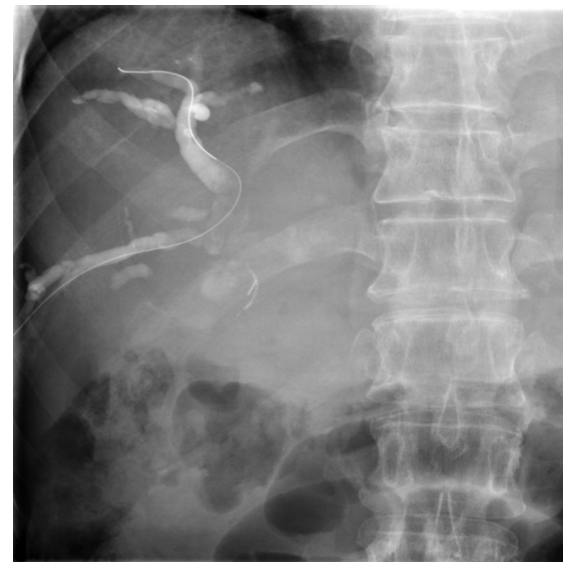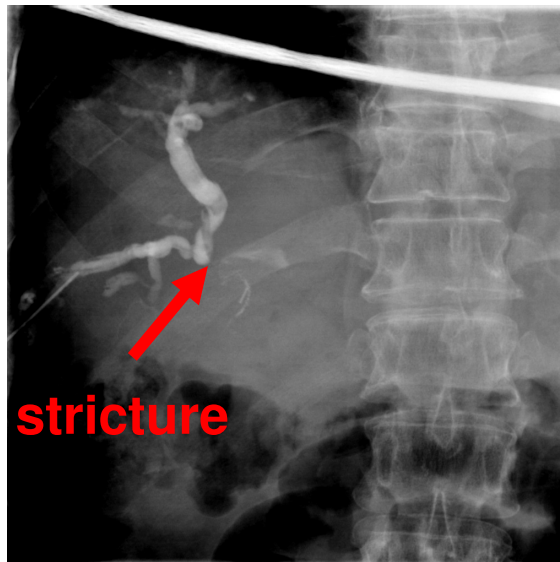


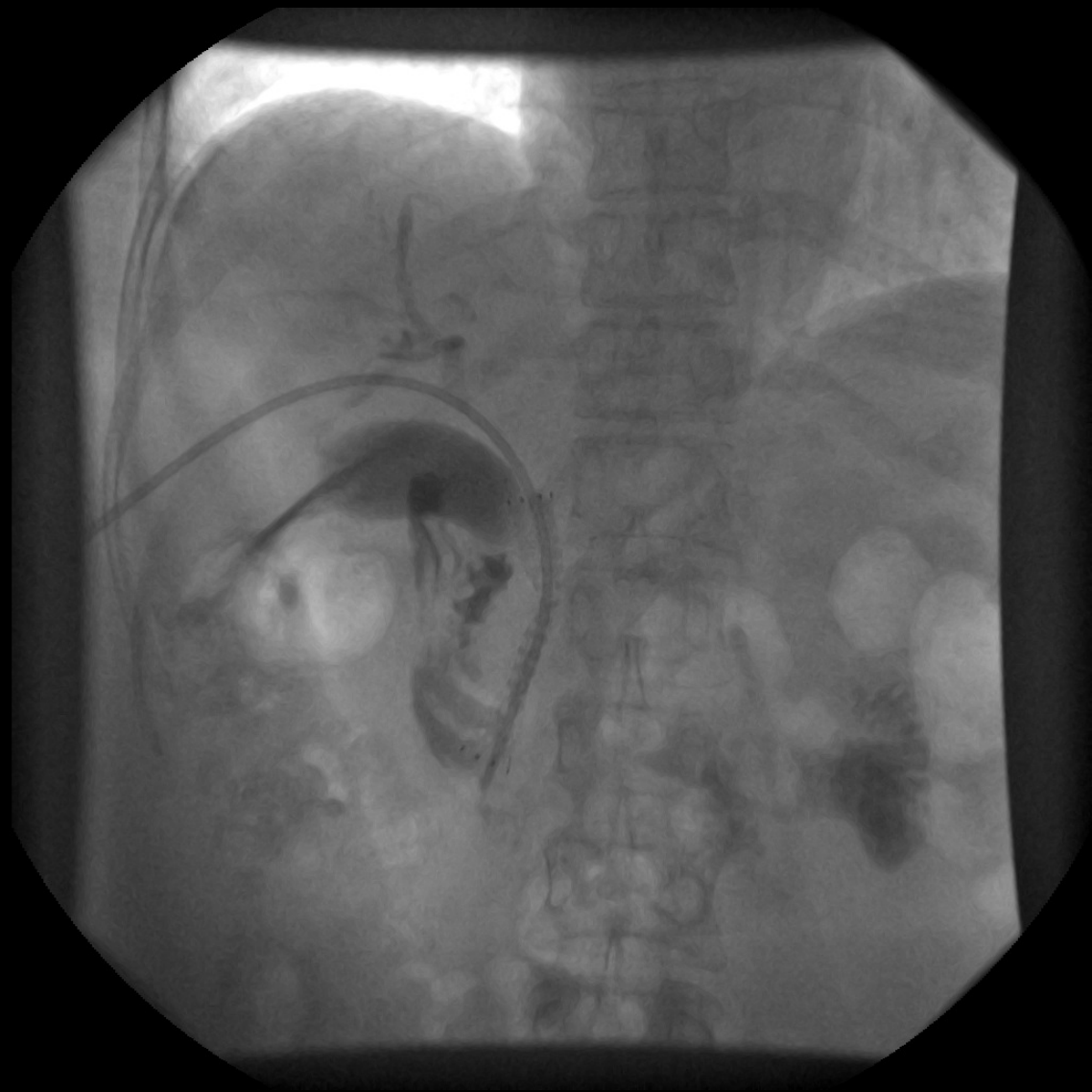
# Ultrasound guided liver abscess drainage

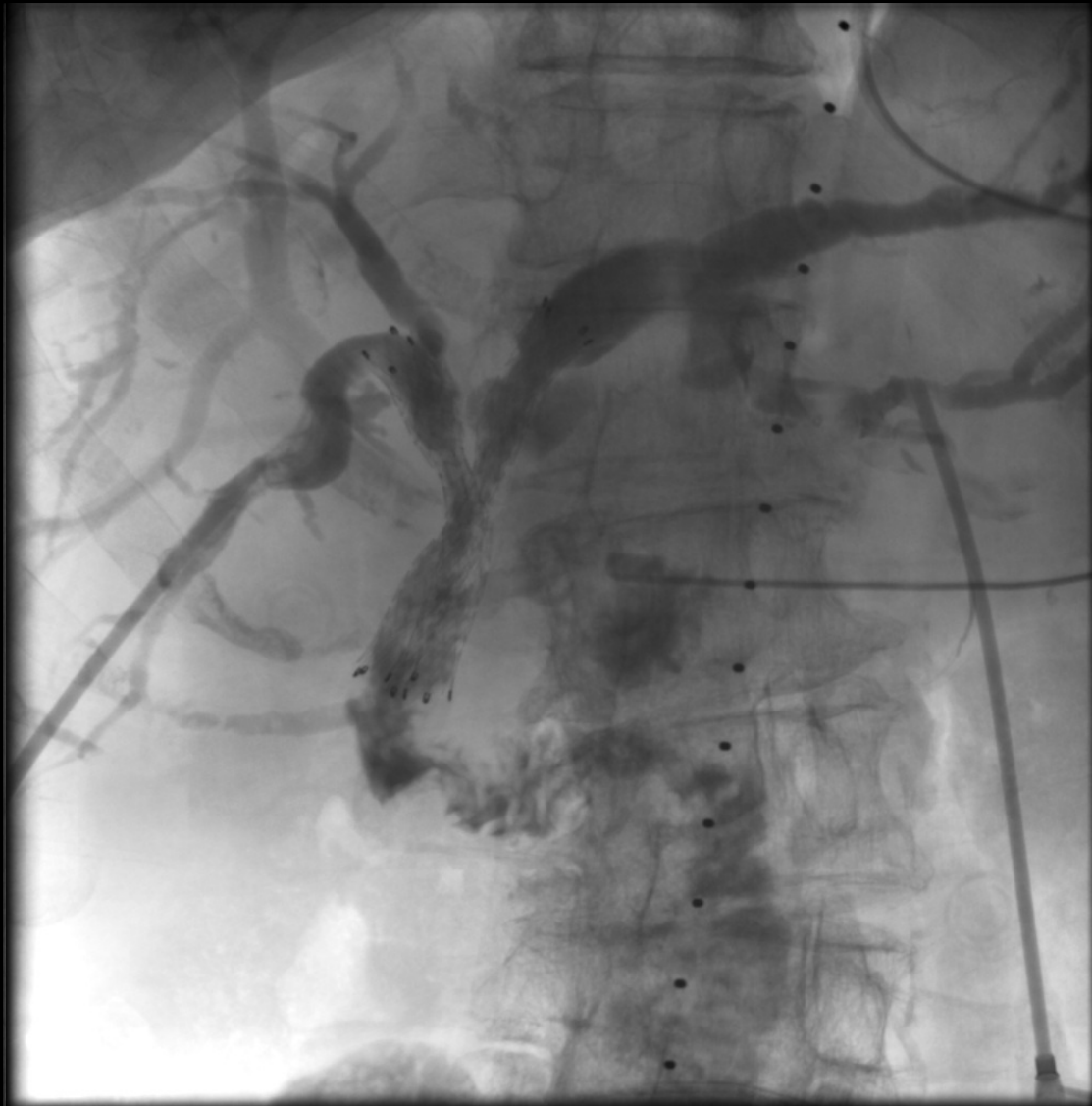


# Percutaneous Transhepatic Biliary Drainage (PTBD)

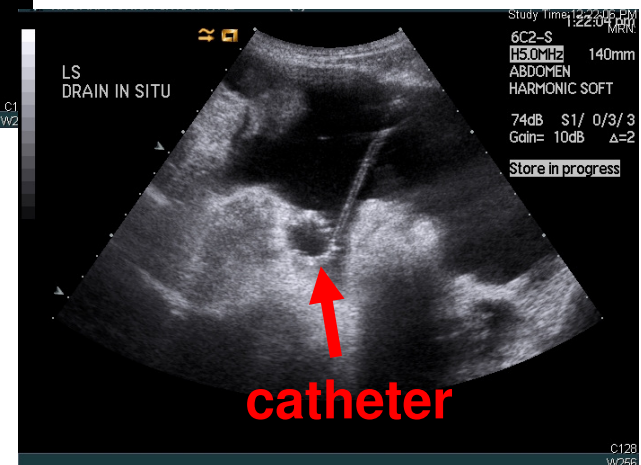
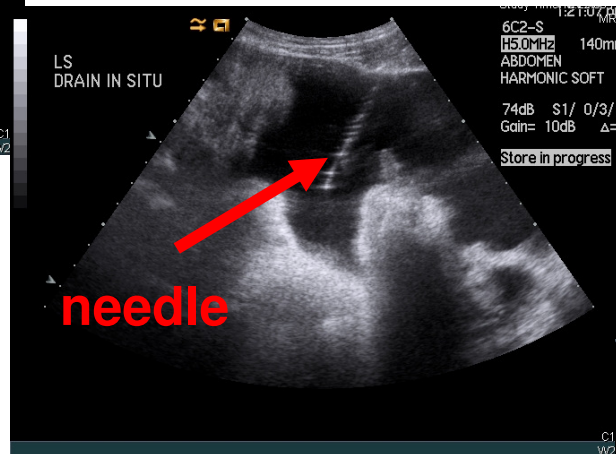
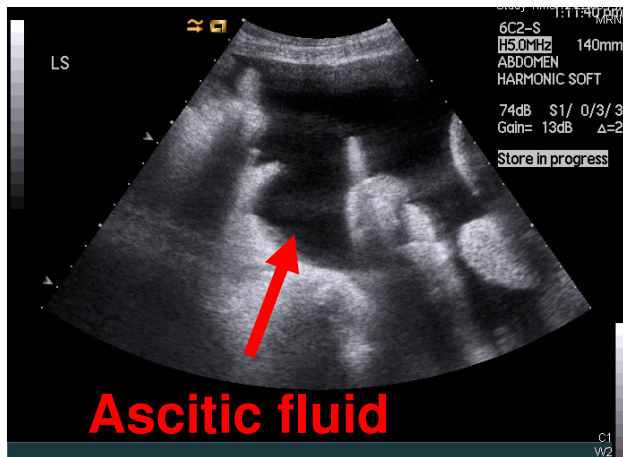
## 经皮经肝胆道引流治疗 for Malignant Biliary Obstruction



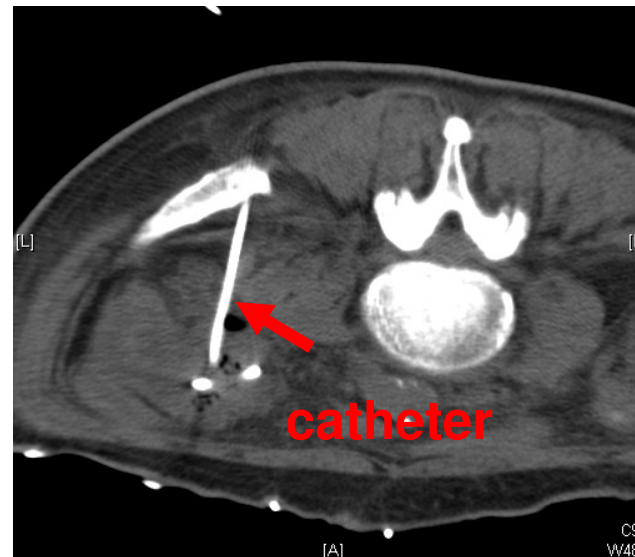
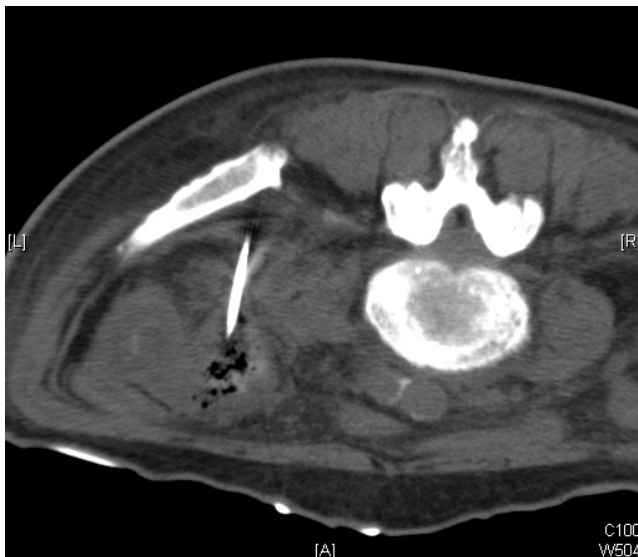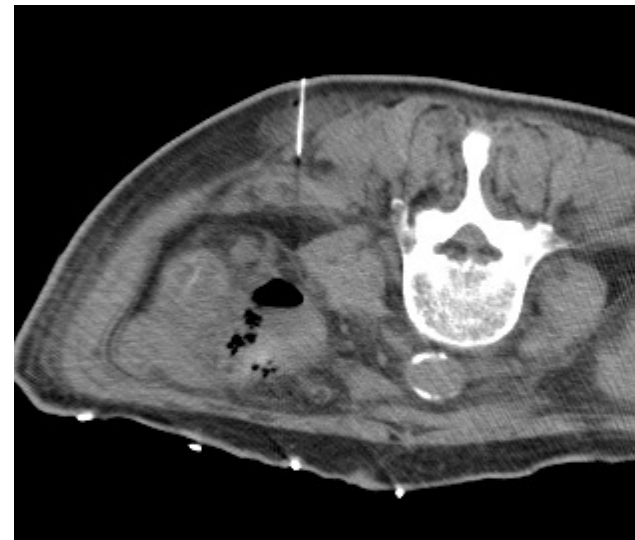

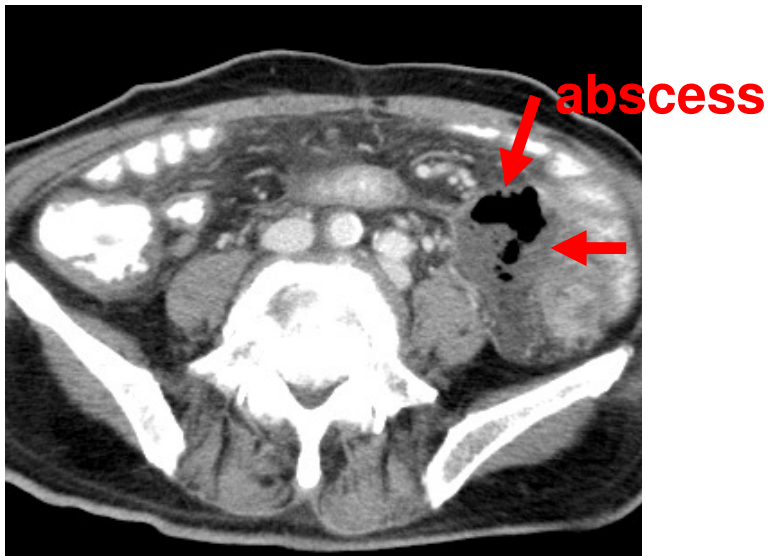


# Ultrasound guided drainage of ascites



# CT guided abdominal abscess drainage

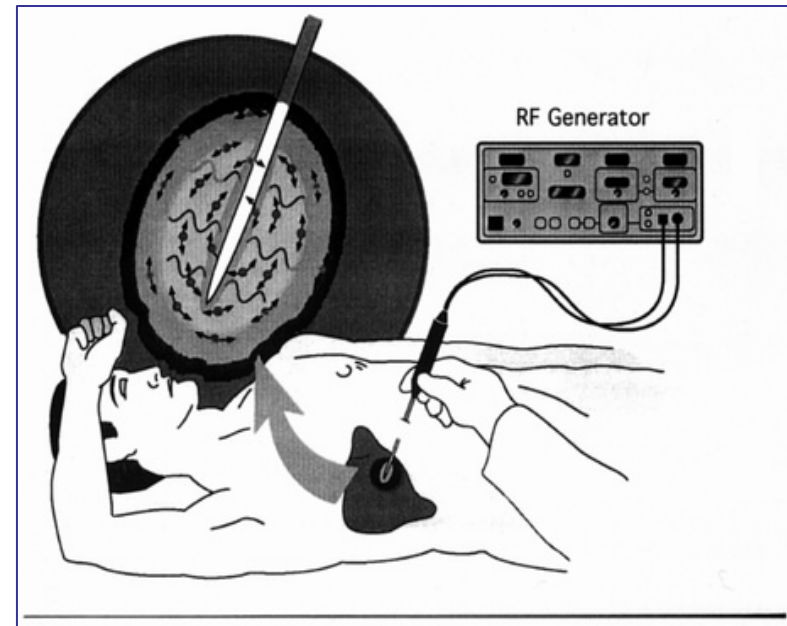


# **Radiofrequency Ablation (RFA)**

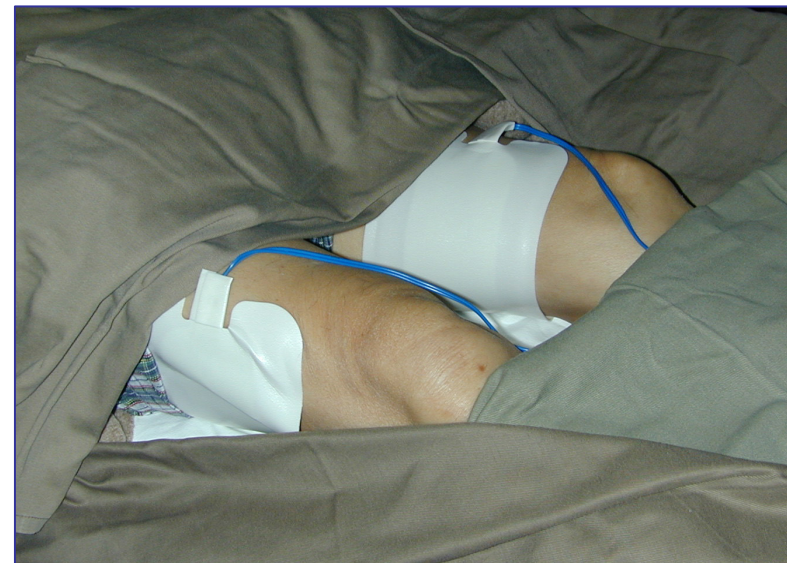射頻能量導管消融術

# RFA: Mechanism

- 17-20 gauge RF electrode
- Thermal coagulation necrosis

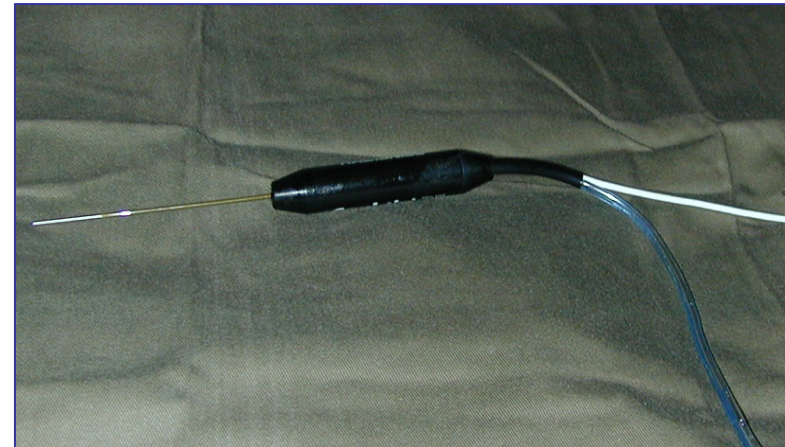


- Reference electrodes (large conductive pads)

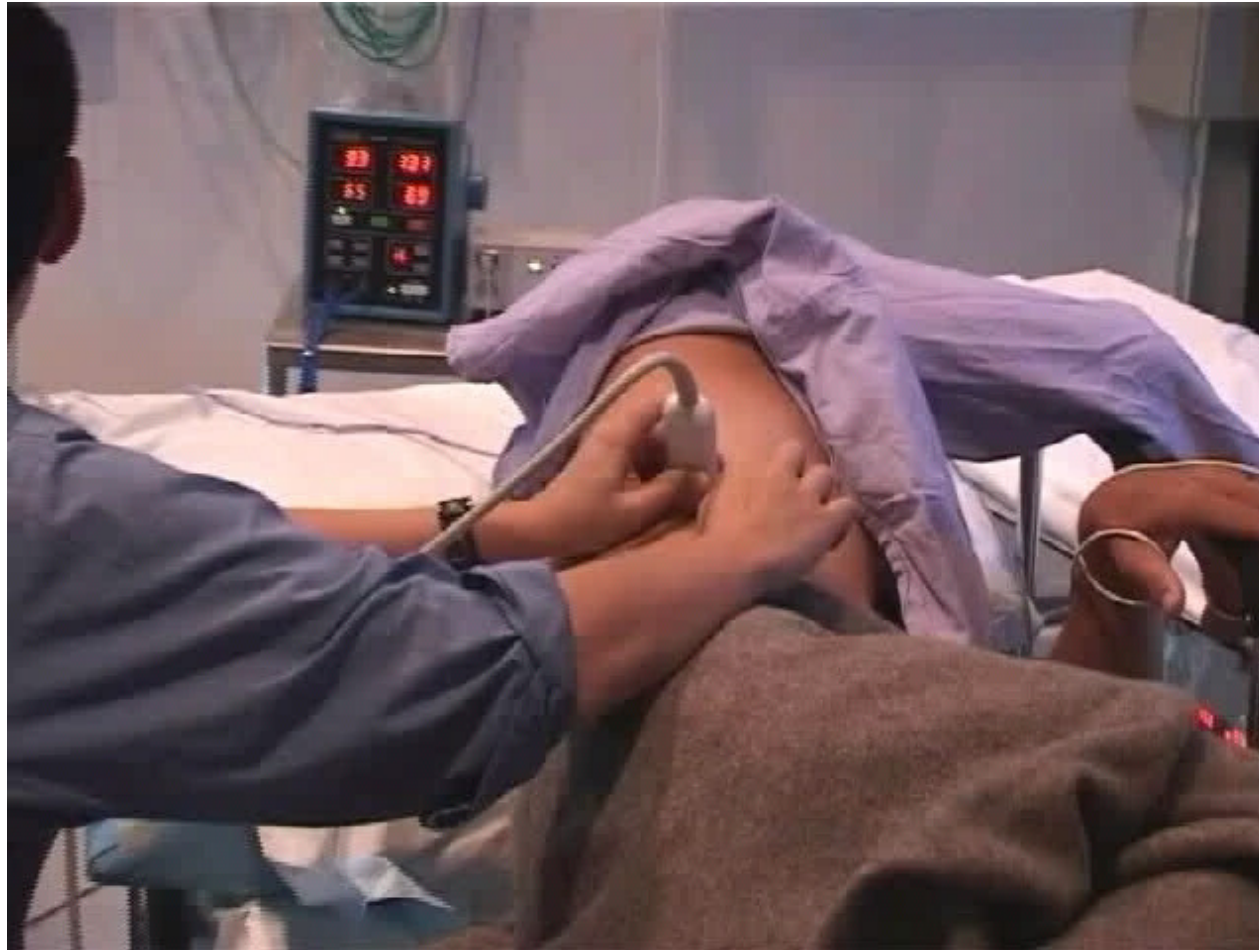

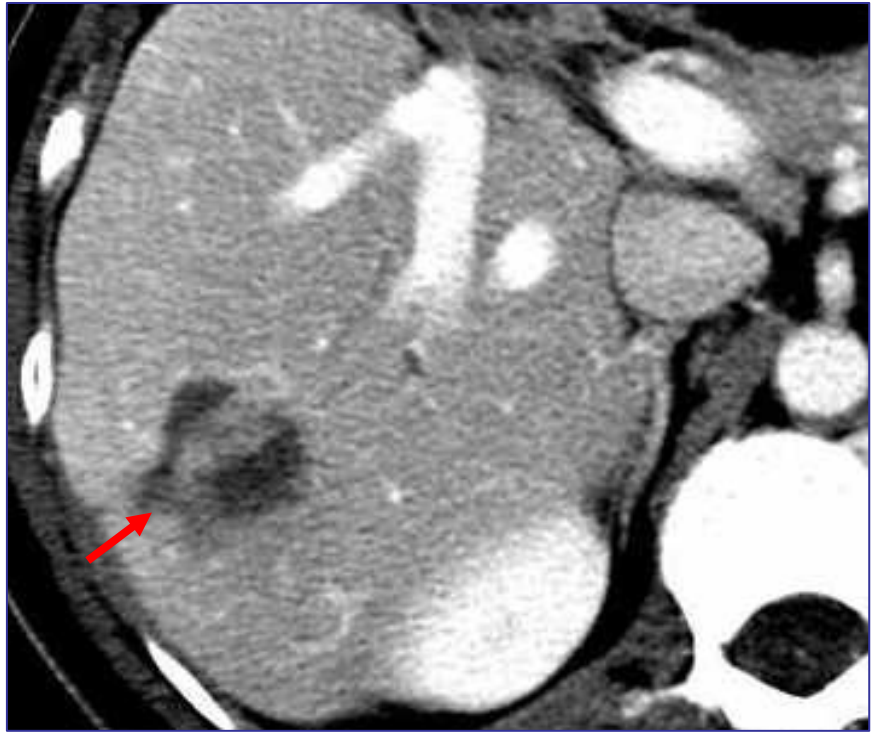
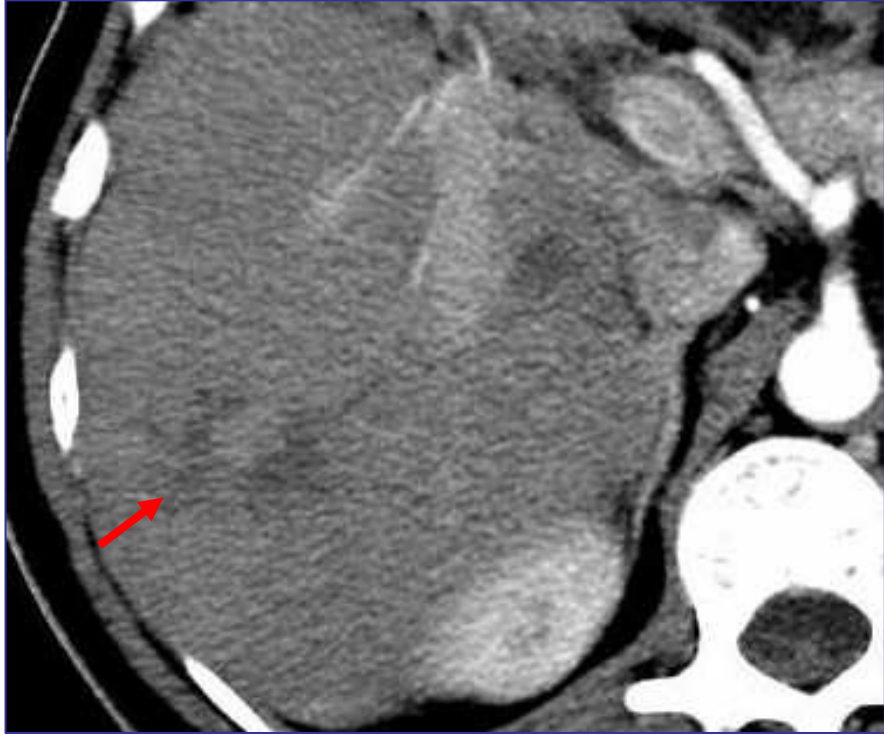# Cooled-Tip Electrodes

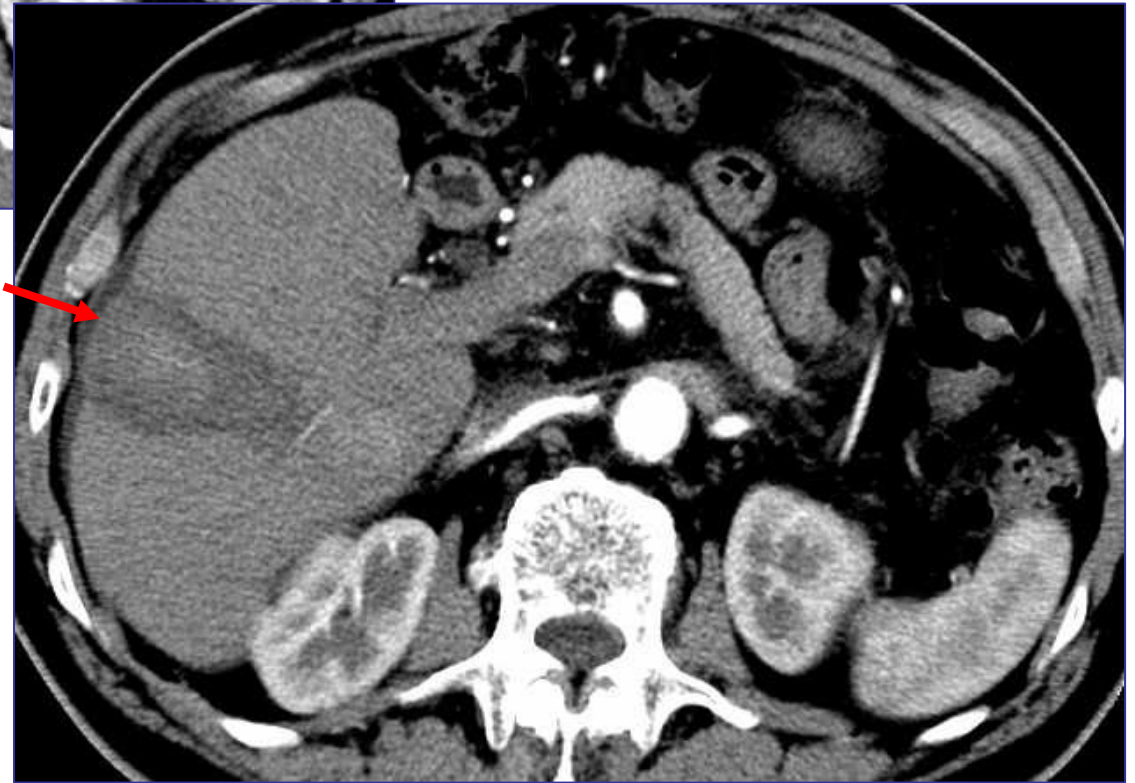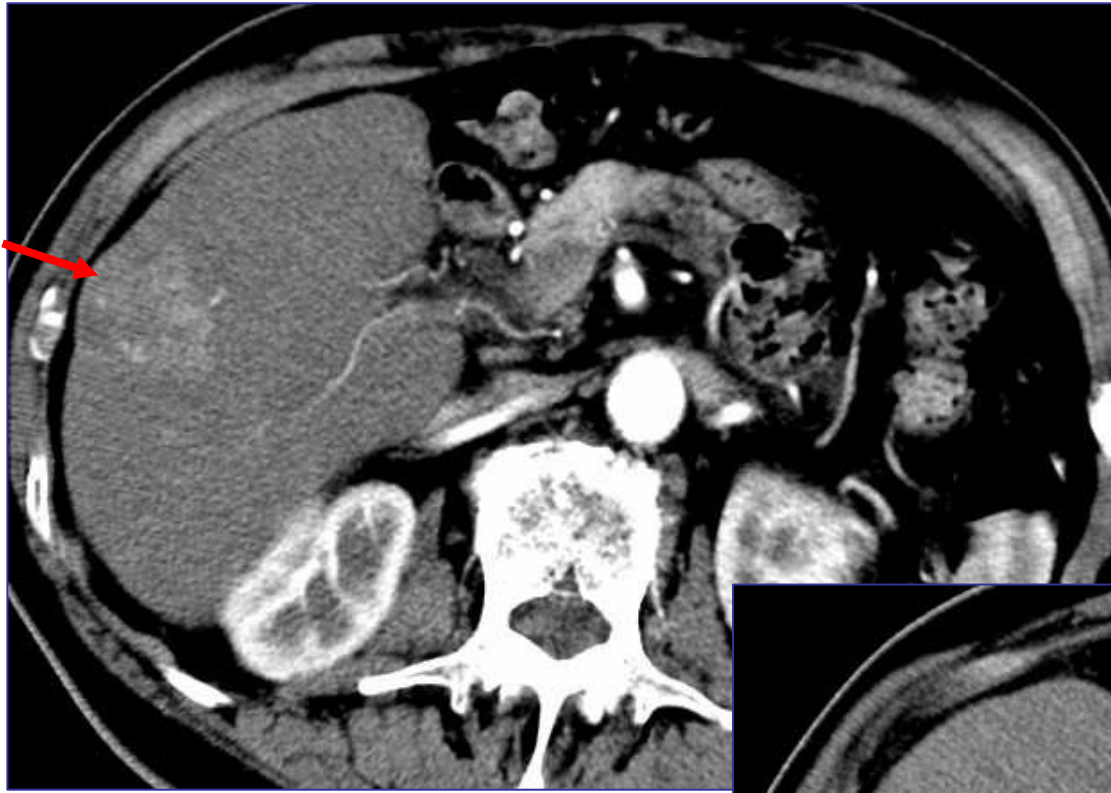- Patented electrode (17-gauge) circulates water internally to cool the tissue around the electrode

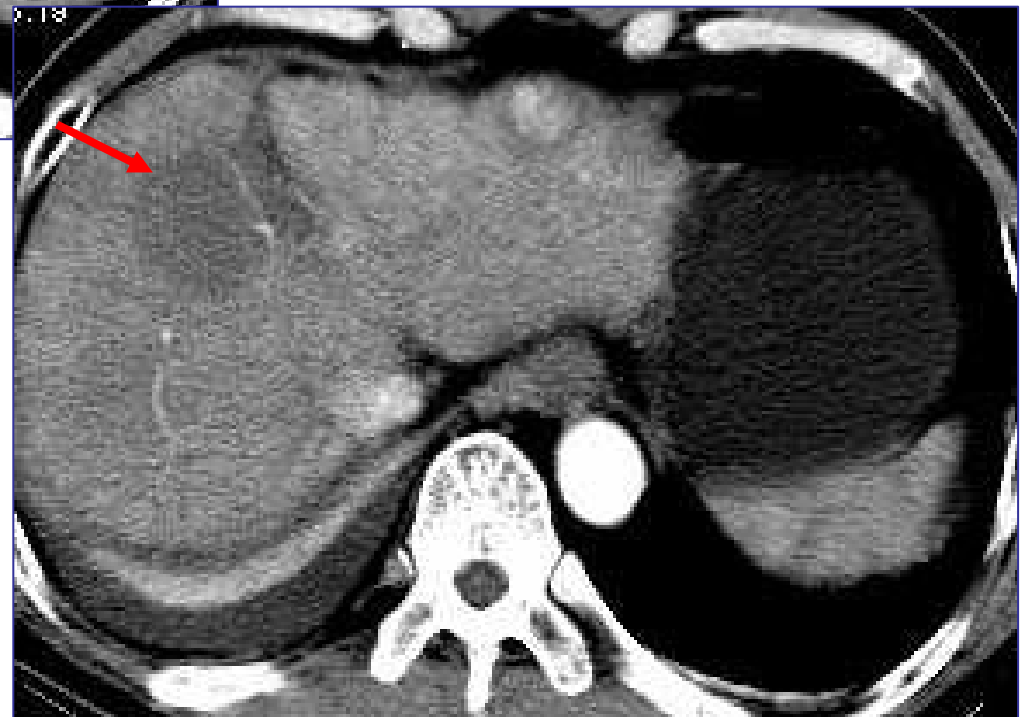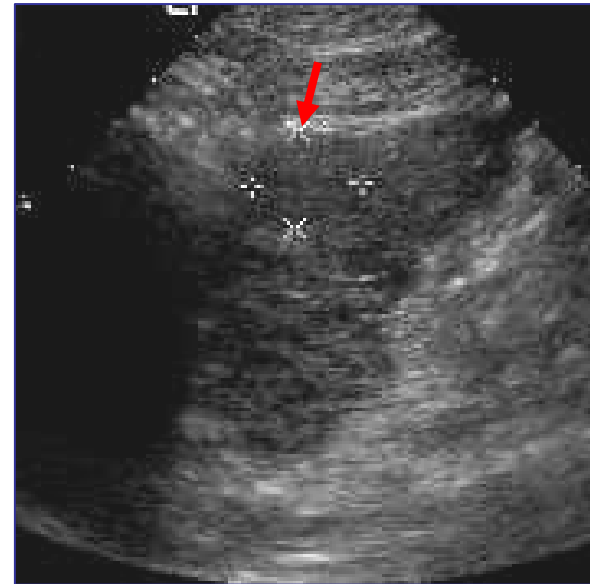
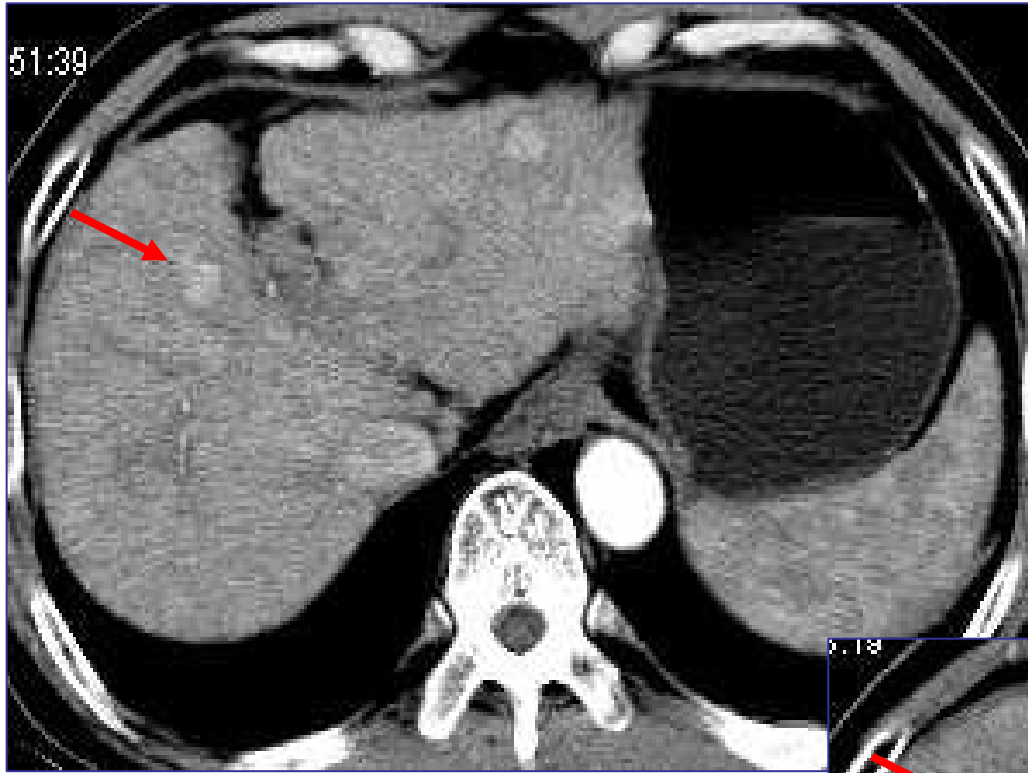


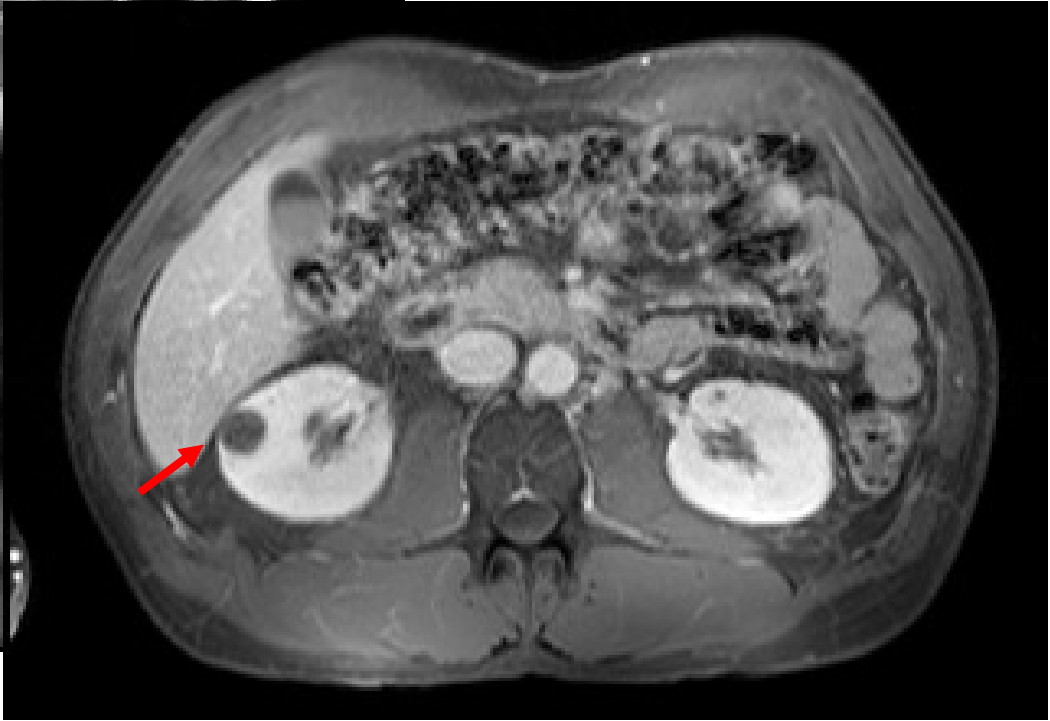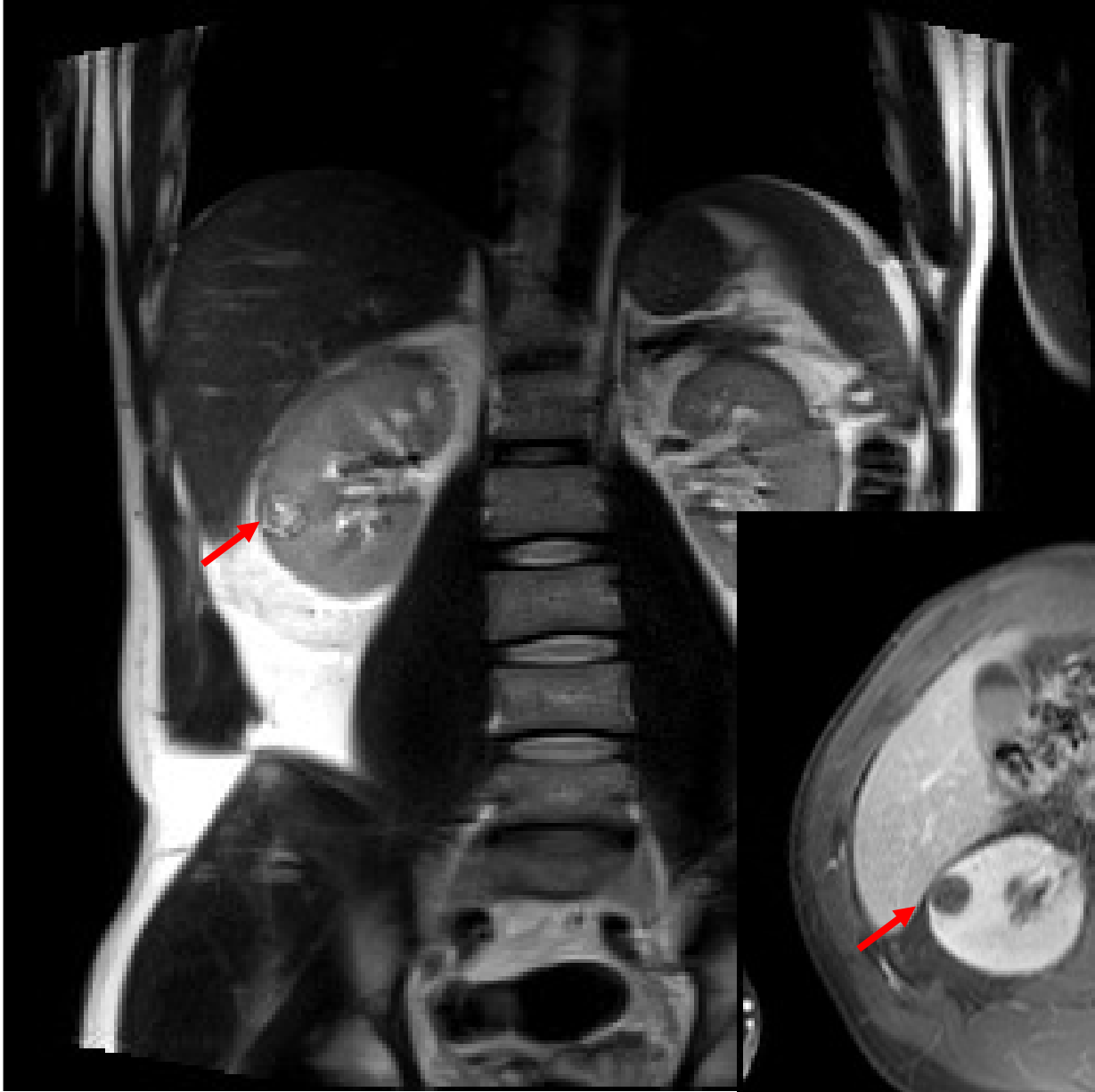
# Ultrasound guided RFA of liver lesion

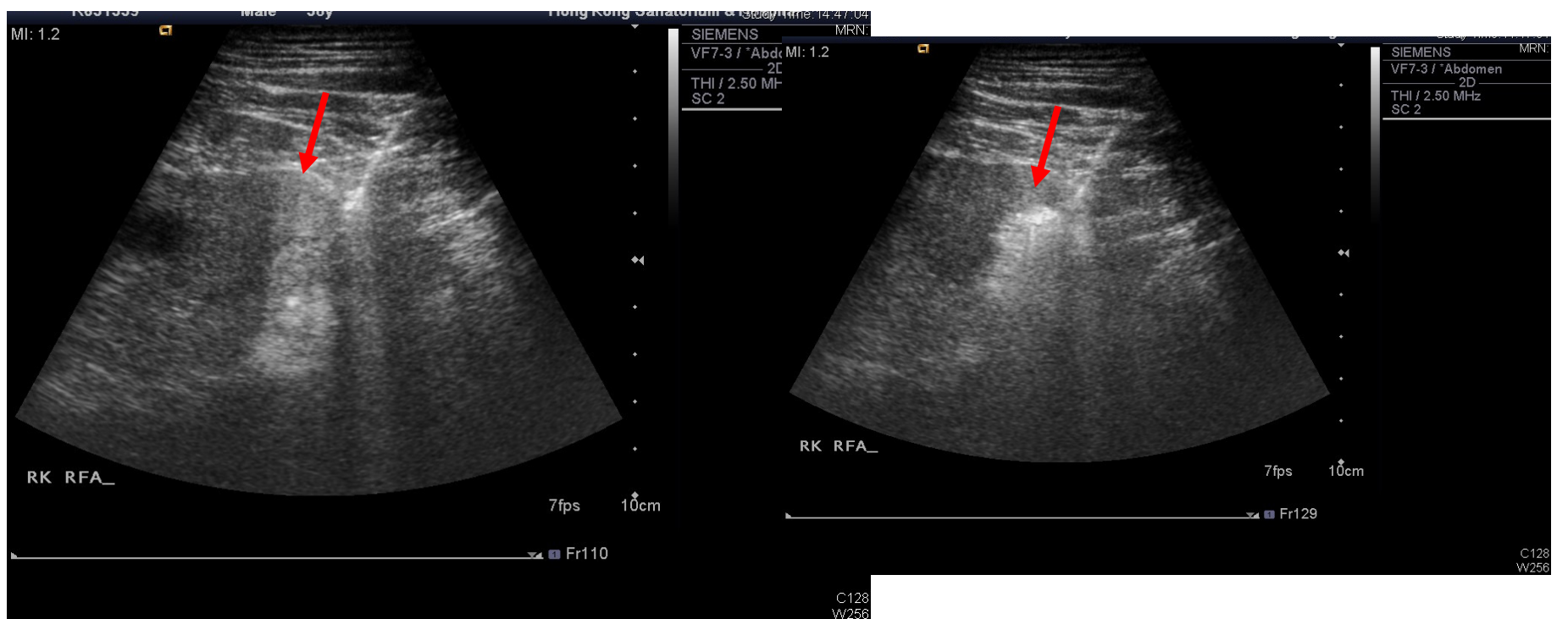
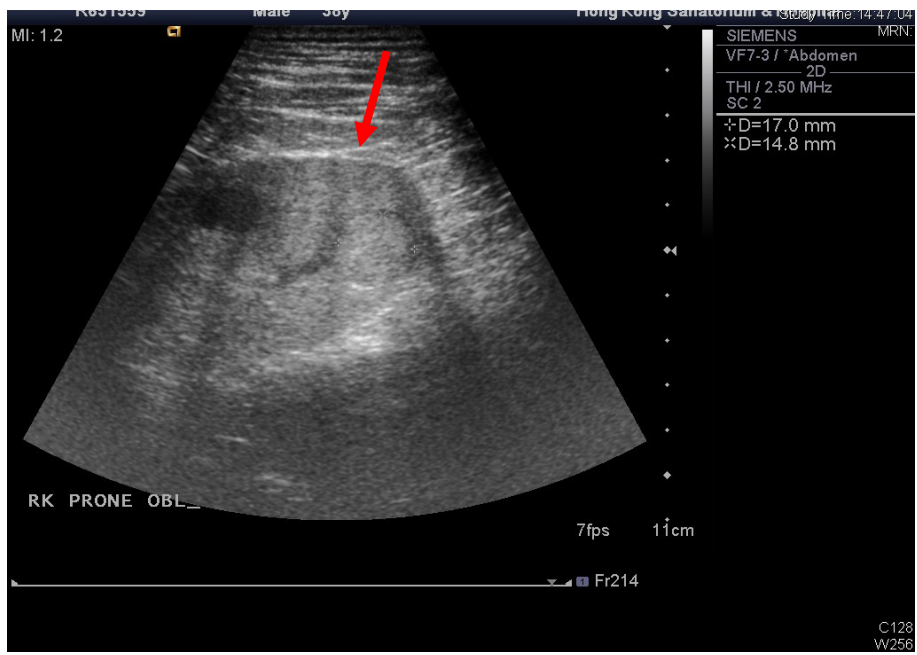




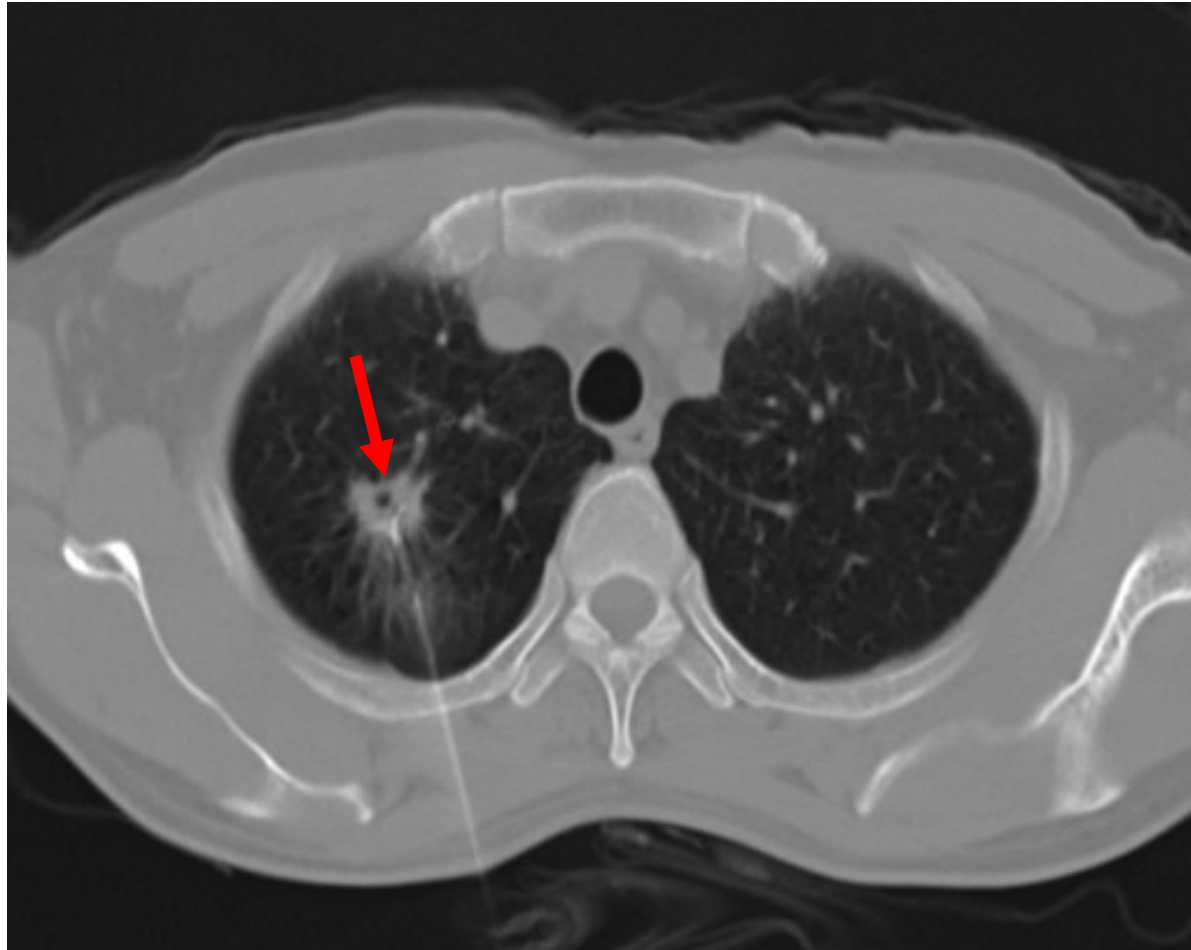







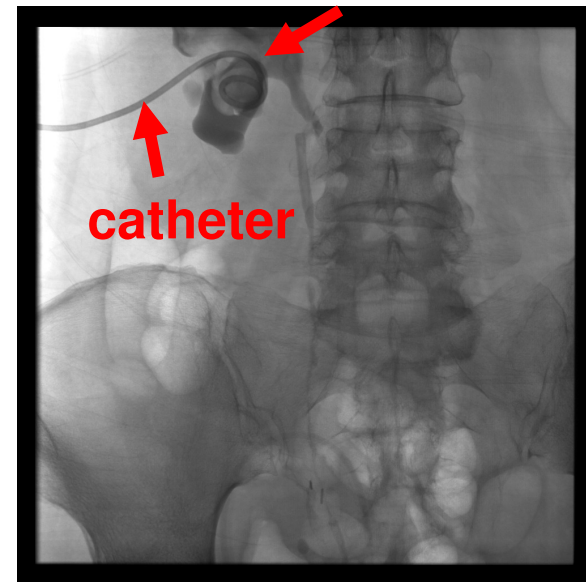
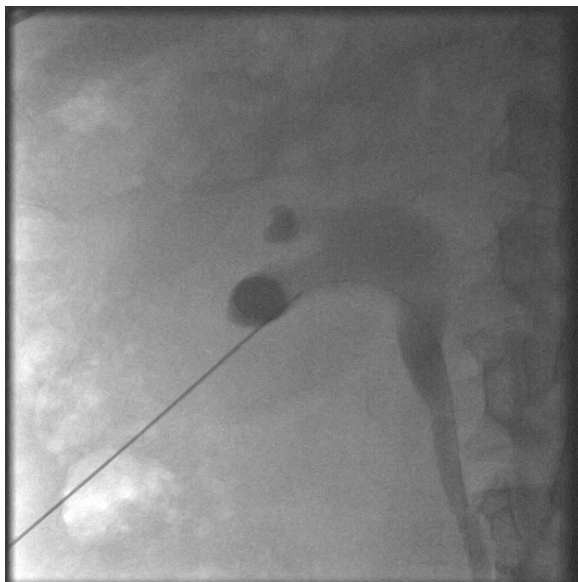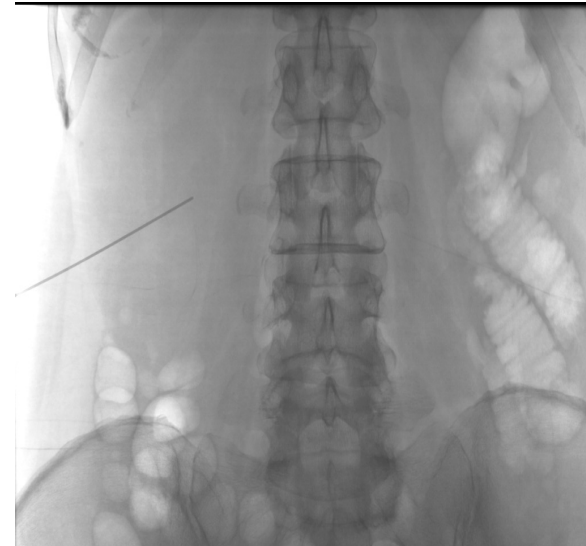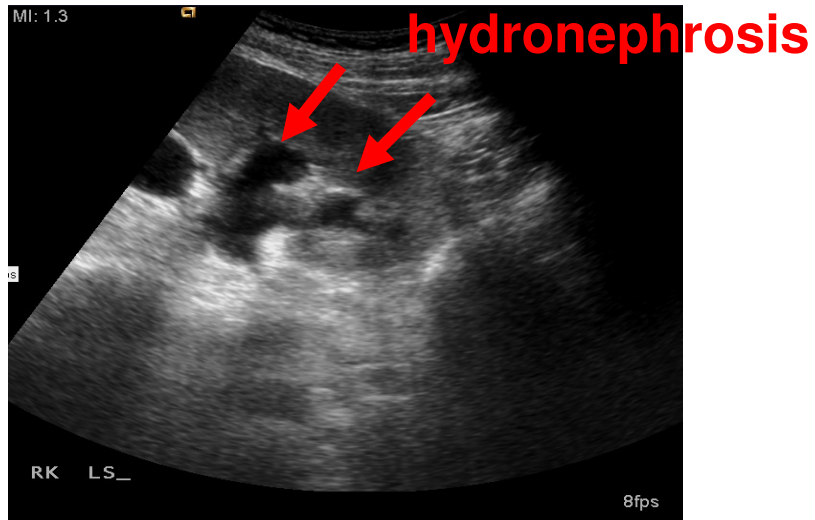
# Radiofrequency Ablation of Lung

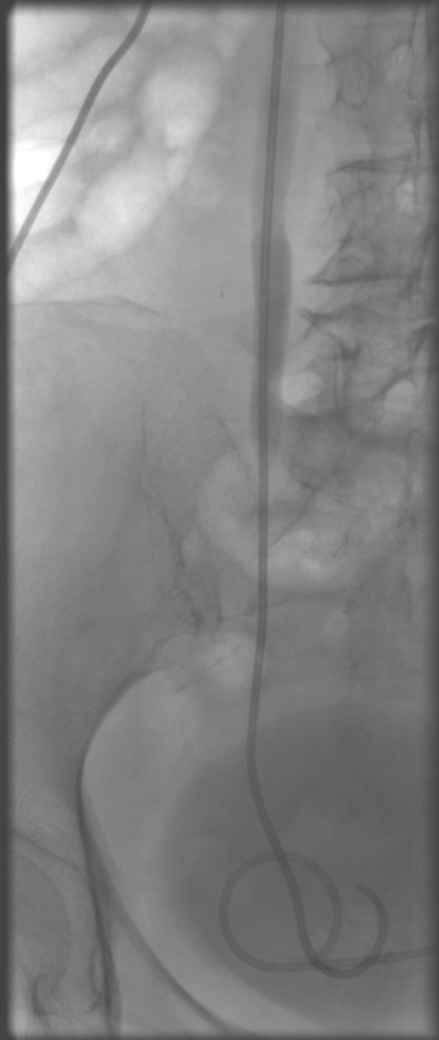


# Renal and prostate Interventional Procedure

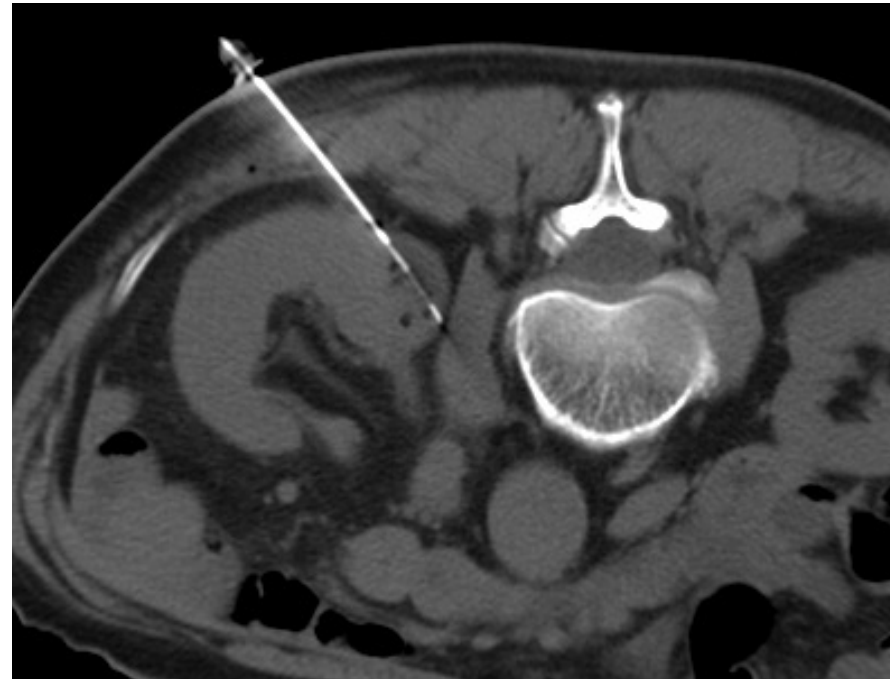
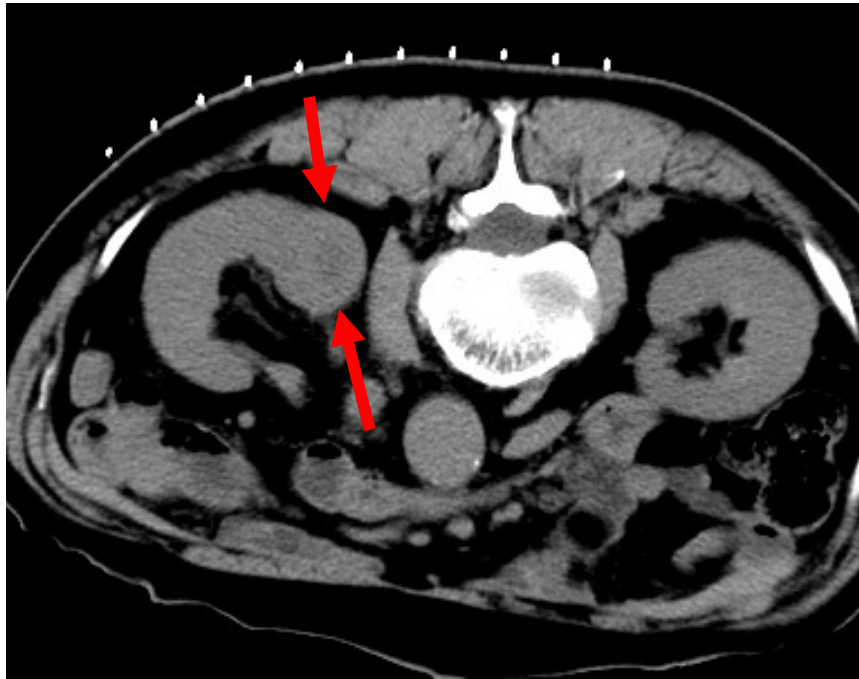
# Percutaneous nephrostomy (PCN)

## 經皮腎造口術

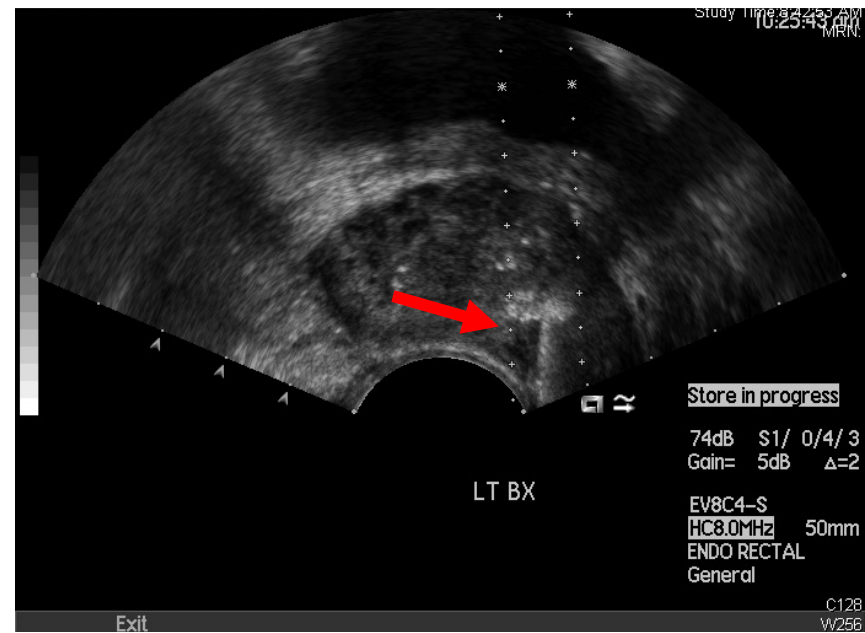
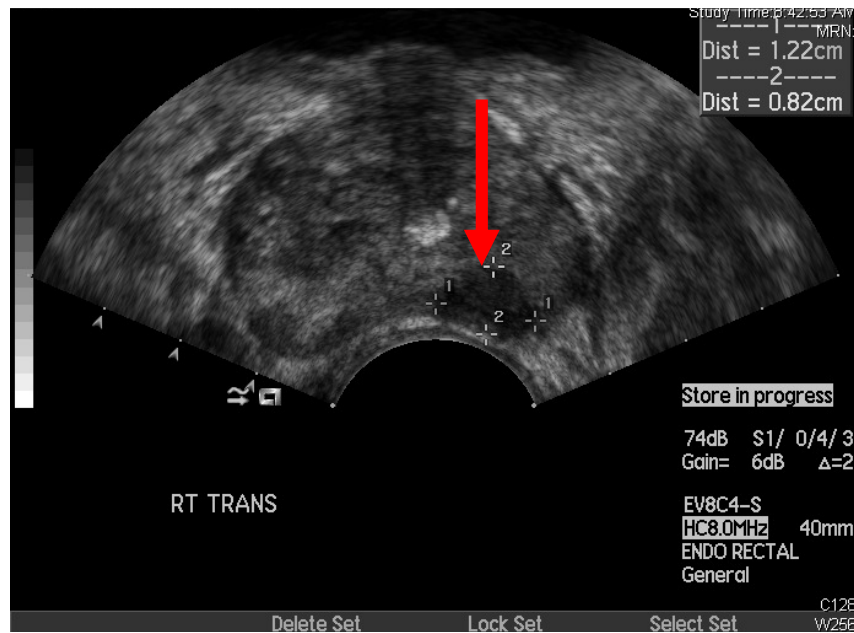




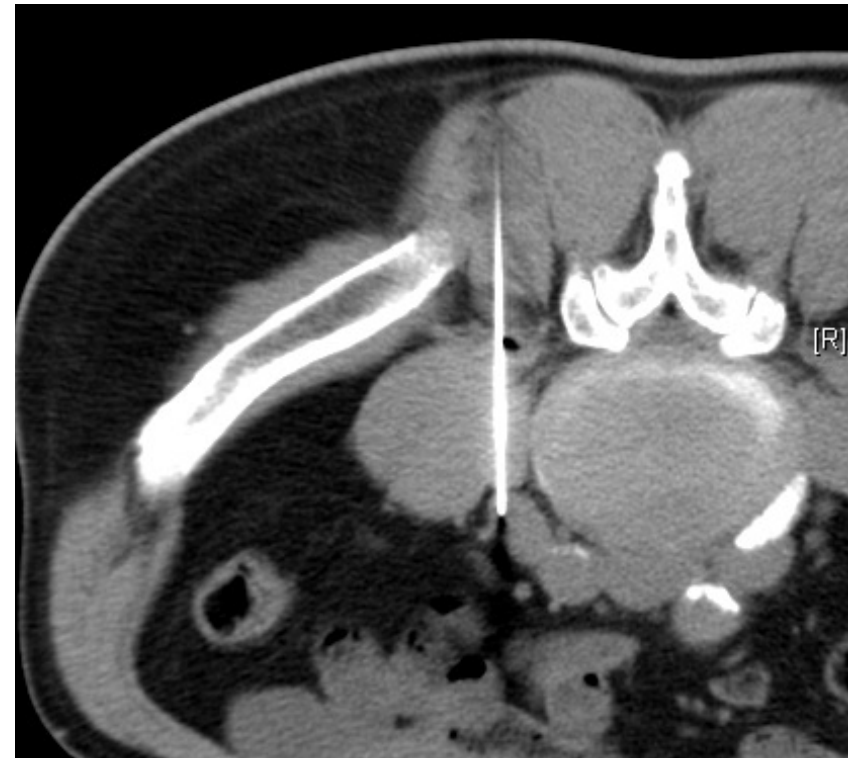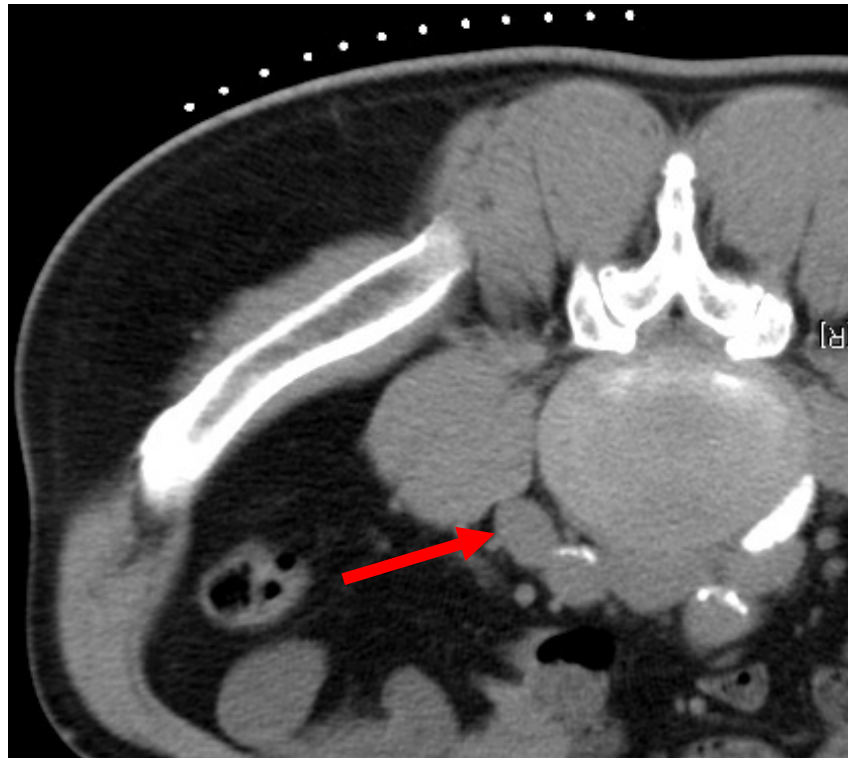
# CT guided renal mass biopsy



# Transrectal ultrasound guided prostate biopsy

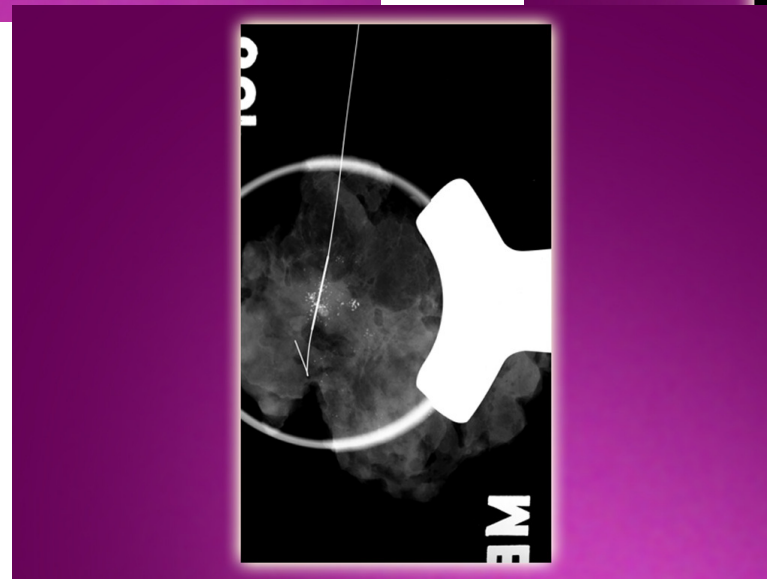
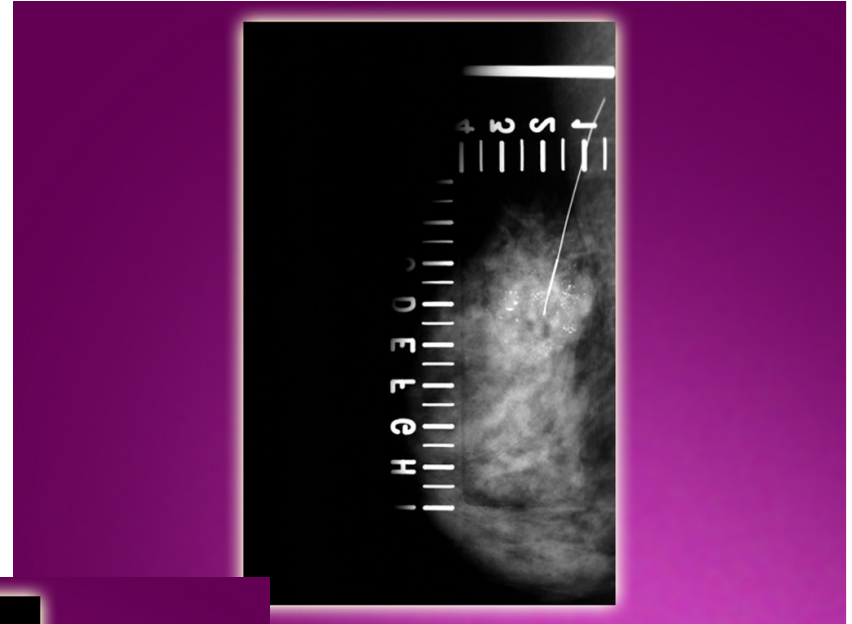



# CT guided iliac lymph node FNA

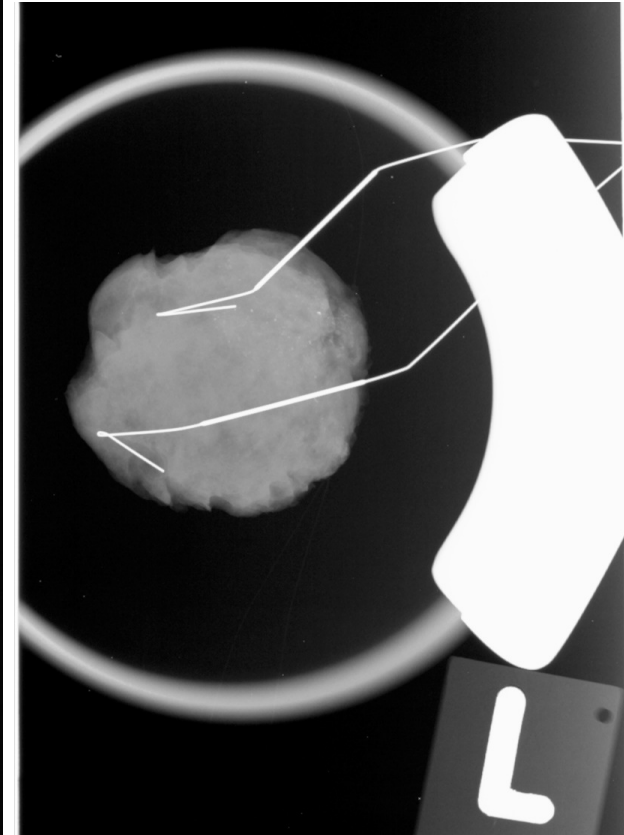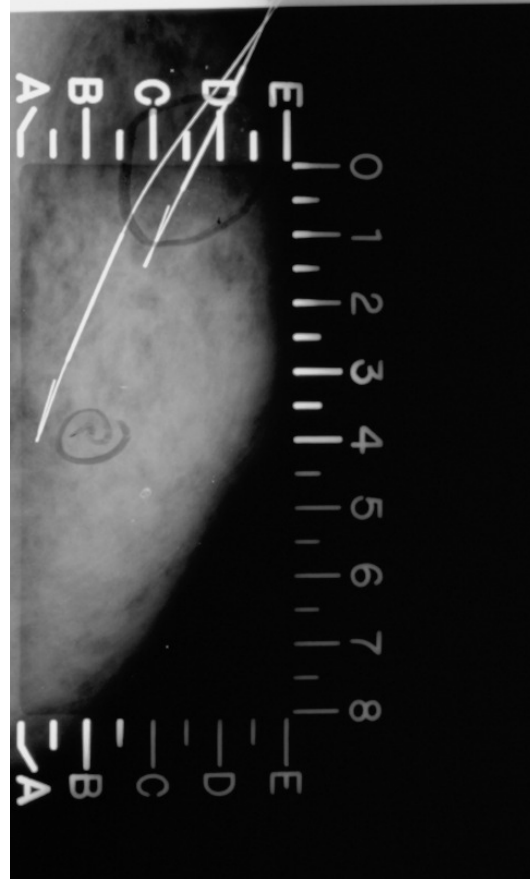
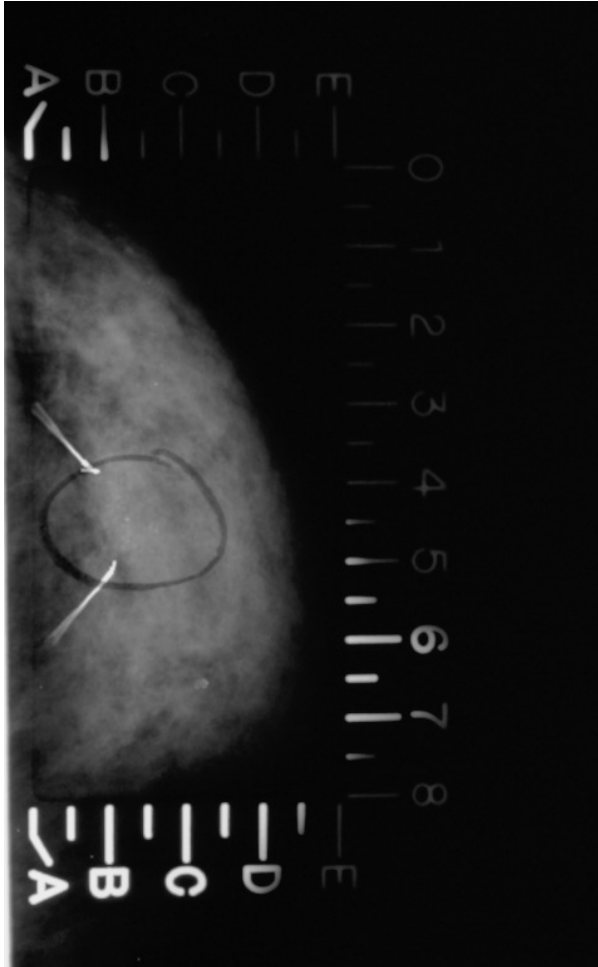


# Breast Interventional Procedure

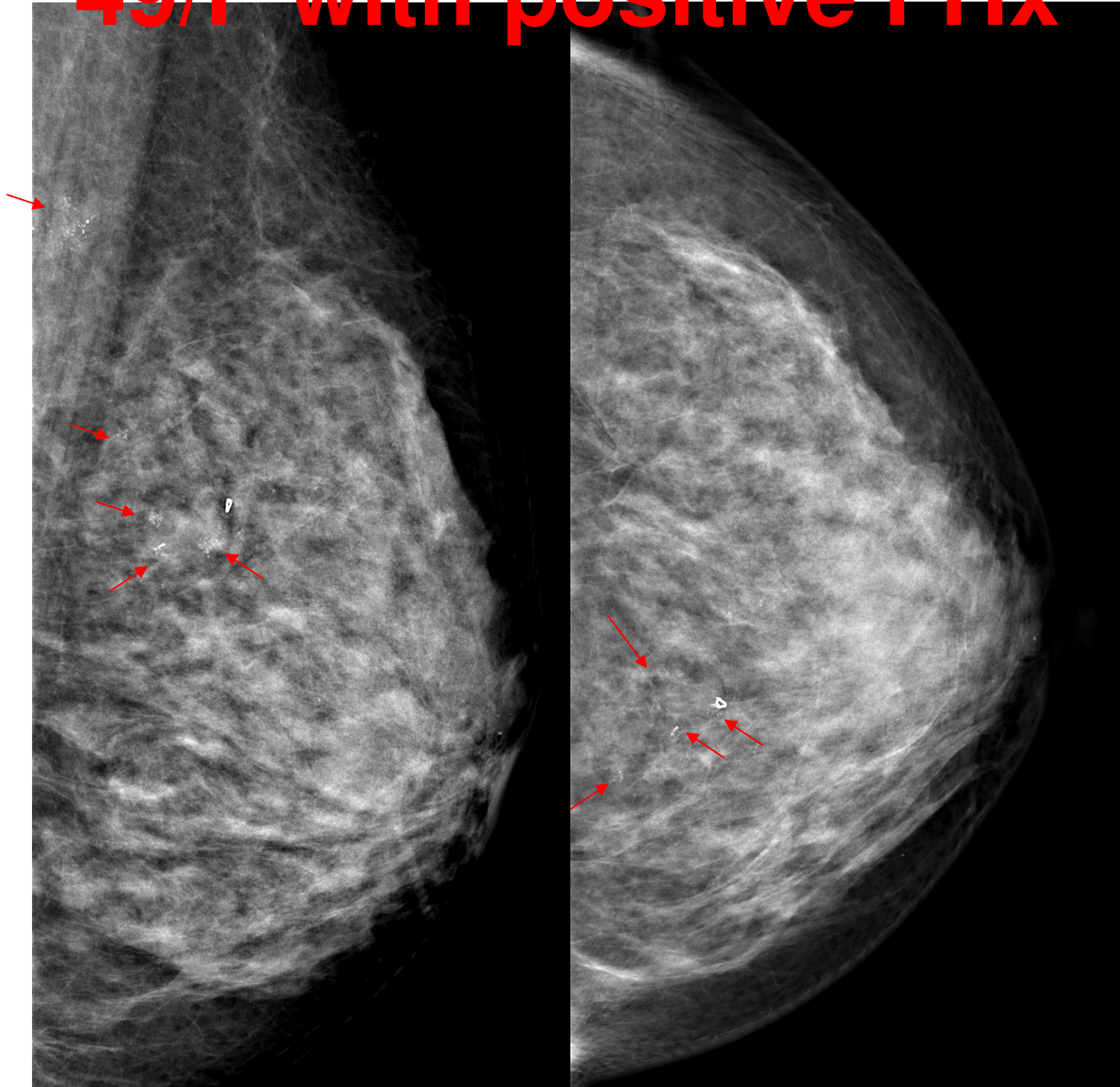
# Mammographic Guided Breast Needle Localization



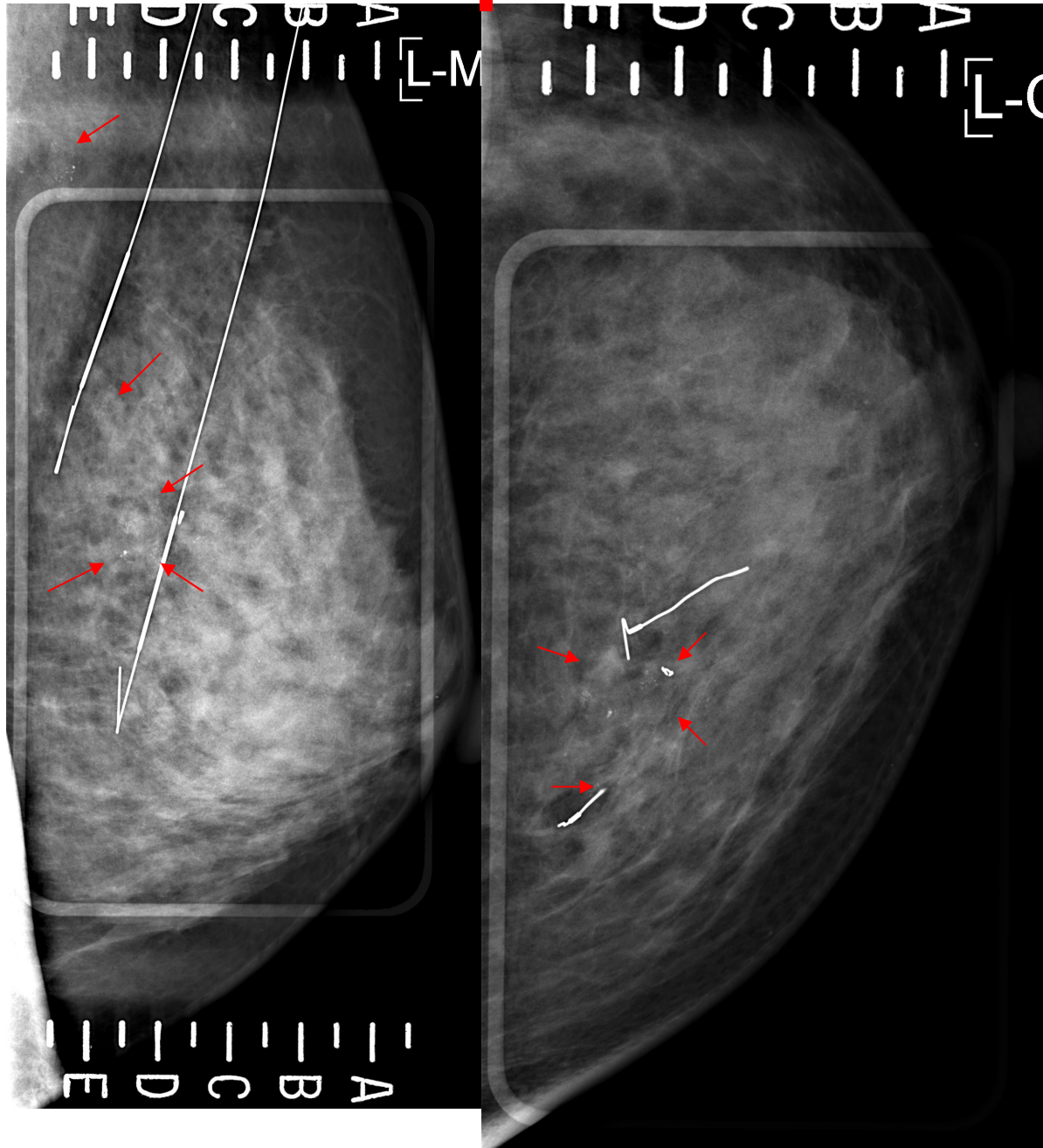
# Needle Localization (2 wires)



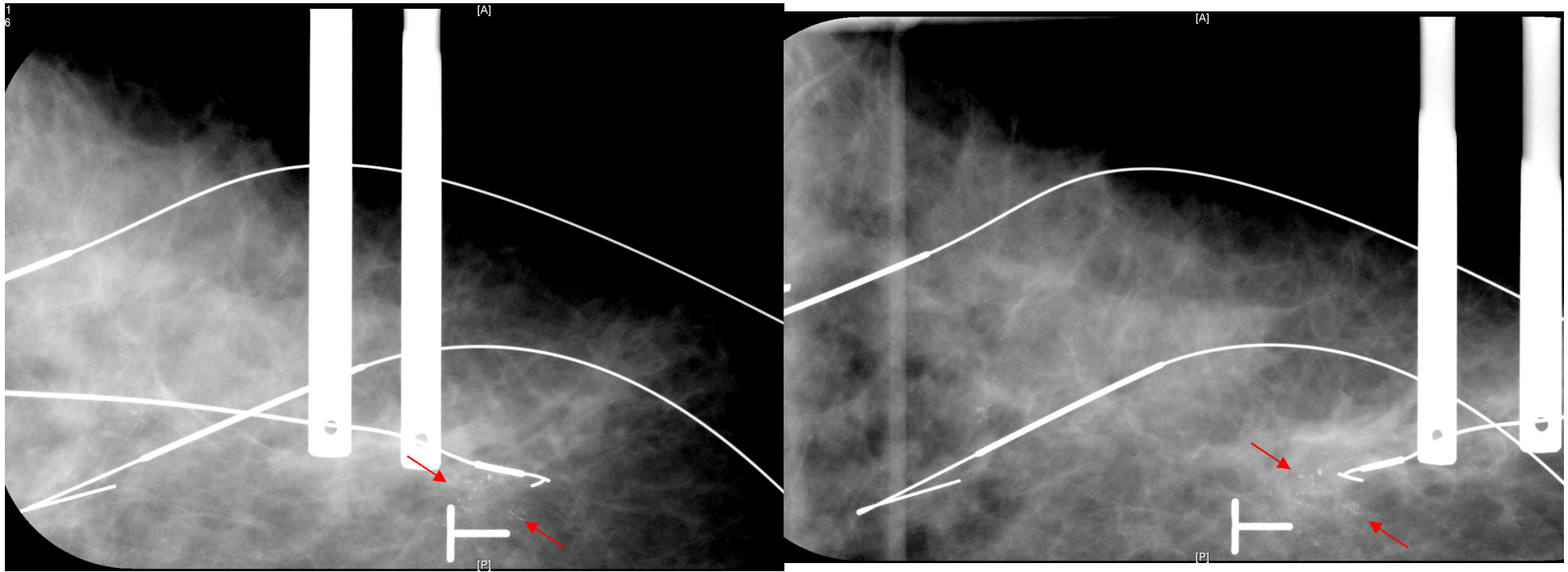
# 49/F with positive FHx



# 49/F with positive FHx

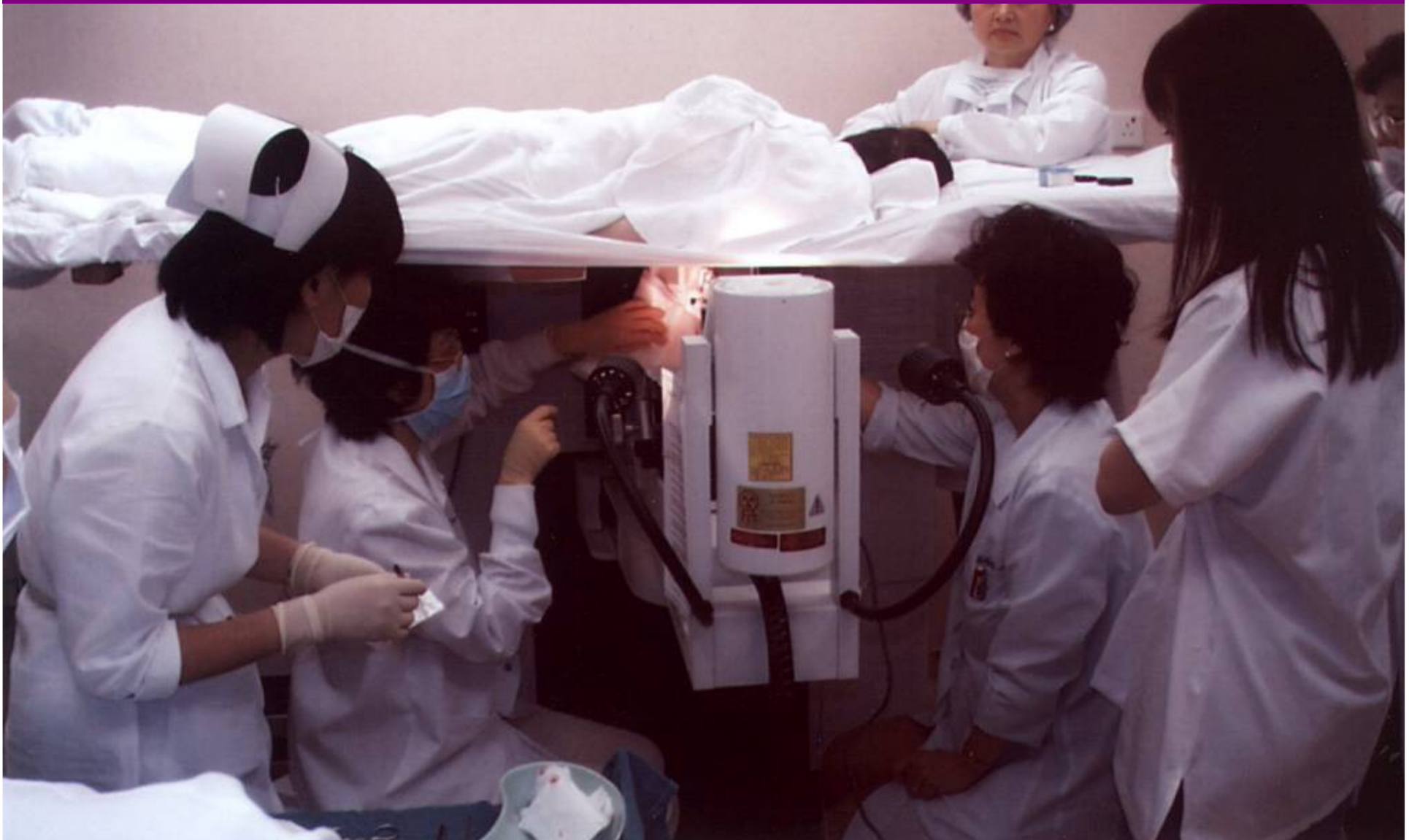

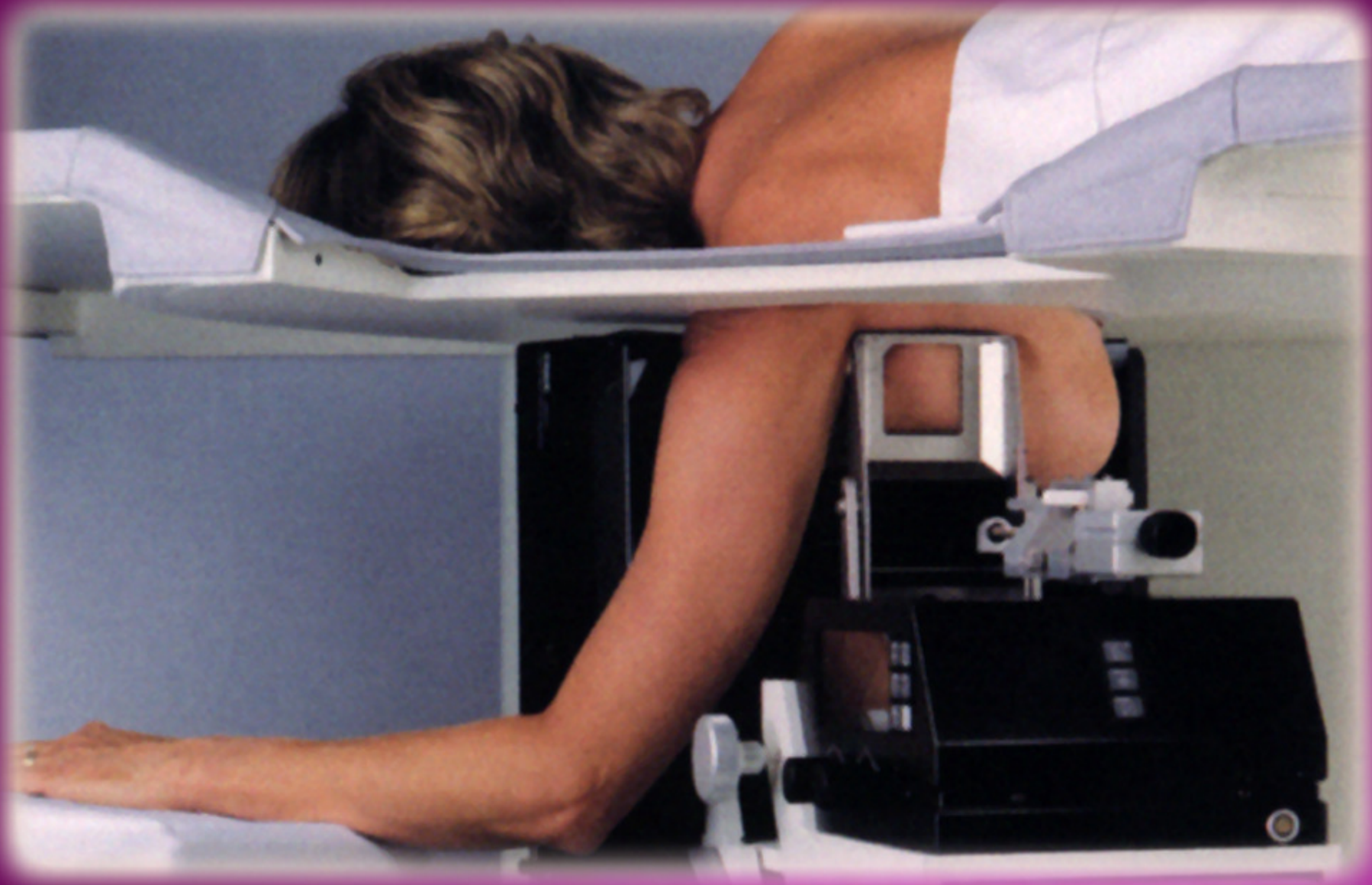# Needle Localization using Stereotactic Technique



# Stereotactic Breast Biopsy Prone Table

## 立體定位活組織檢查



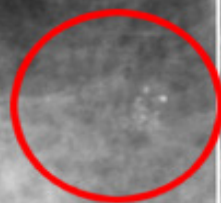


# Vaccum Assisted Biopsy Device



**RMLO**

**LMLO**



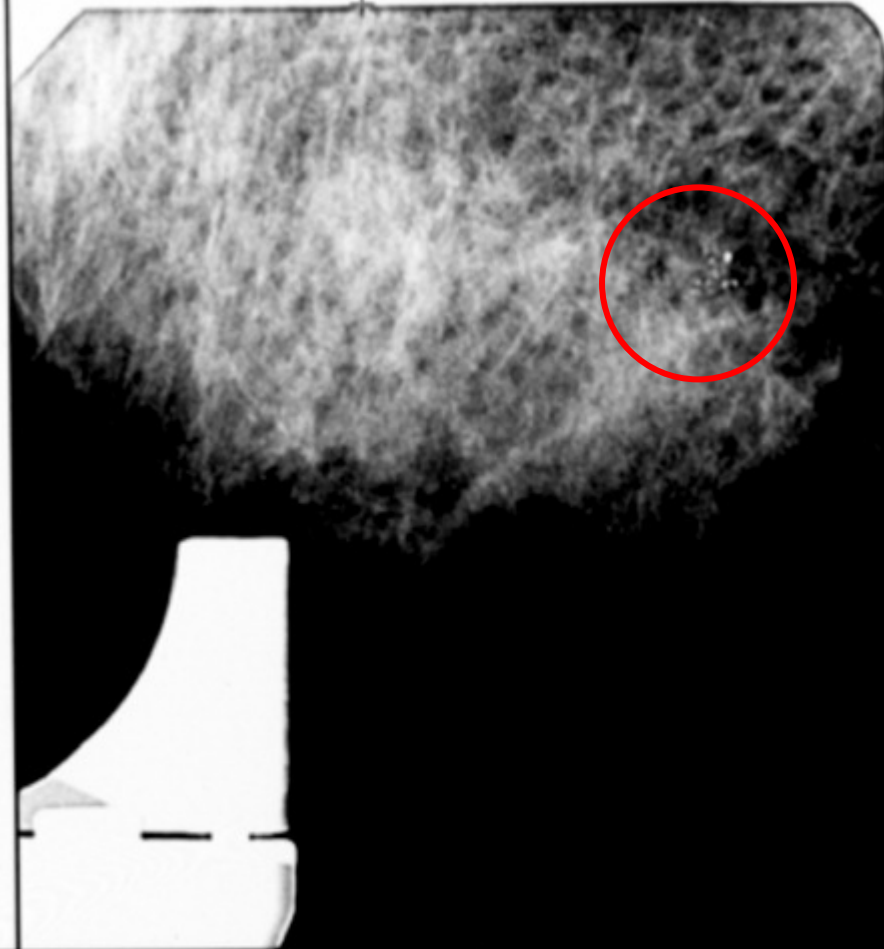
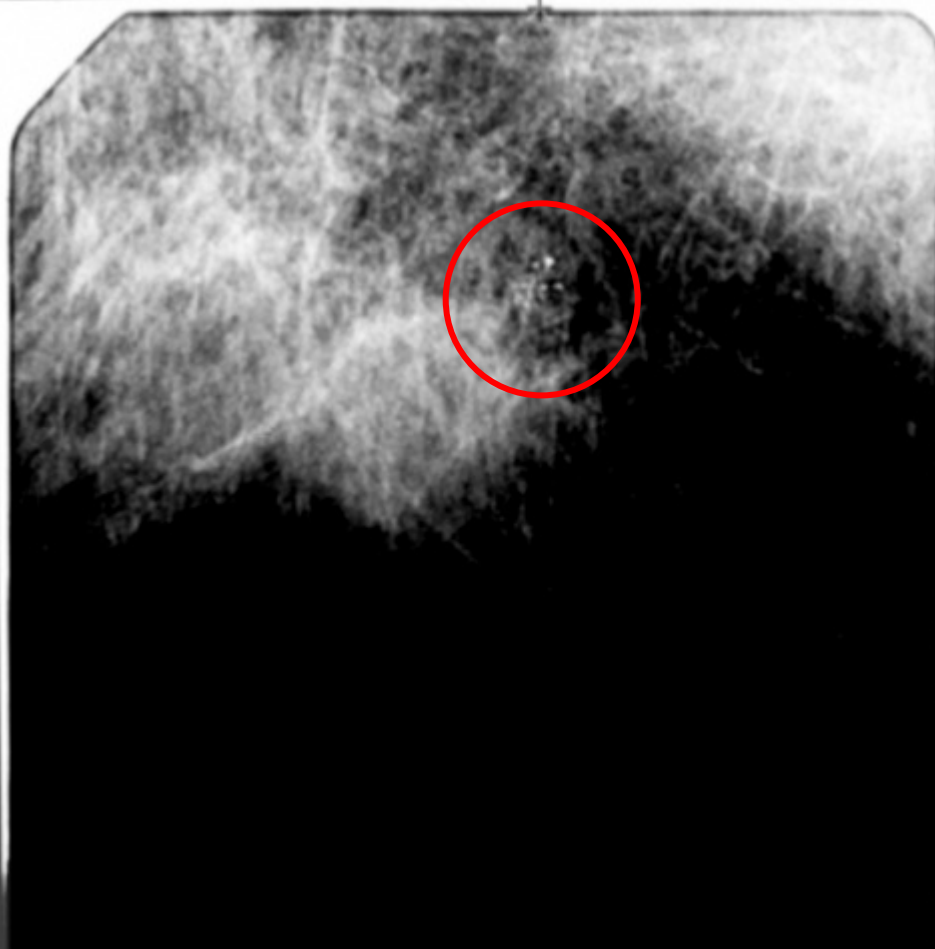
Pt. Name: YIP  
Operator: AL  
Comment : RT.LAT.MED. CALCI HIBB

Exp: 1.00  
mAs: 80.00

Time: 09:13:33  
Mode: 512 F  
View: Stereo

Compression: 42.9  
Comment :

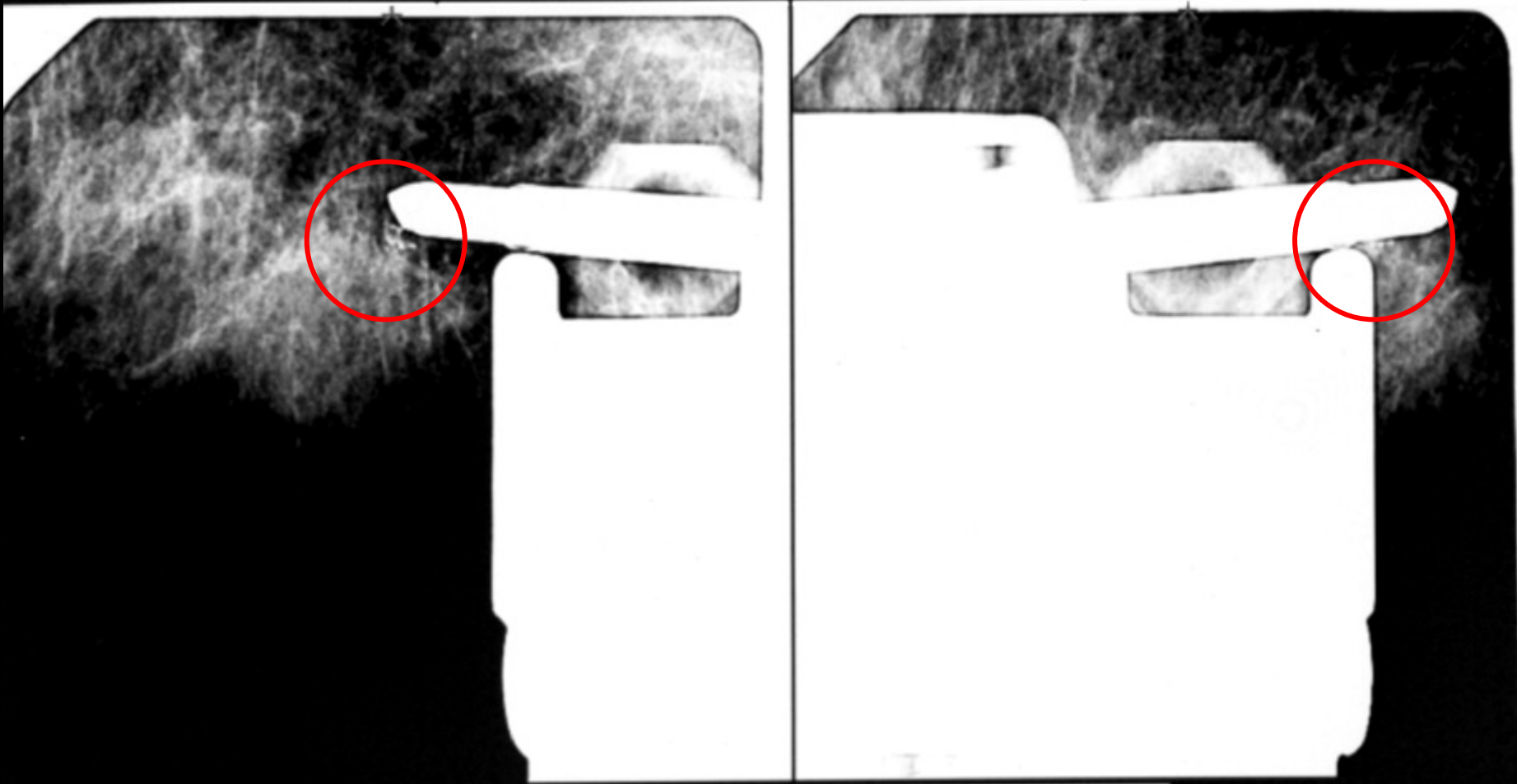
Exp: 1.00  
mAs: 80.00  
Mode: 512 F  
View: Stereo



Stereo Targeting [mm]

	A	B	C	D	E	F	
X Value:							Stereo Target
Y Value:							Multi-Pass
Z Value:							Transmit

Pt. ID : D 0345949-7      kUp: 28      Date: 11-03-1999      kUp: 28      Date: 11-03-1999  
Pt. Name: VIP      Exp: 1.00      Time: 09:47:58      Compression: 42.9      Exp: 1.00      Time: 09:47:44  
Operator: AL      nAs: 80.00      Mode: 512 F      nAs: 80.00      Mode: 512 F  
Comment : PRE.FIRE      View: R Lat Md      Comment :      View: R Lat Md



Stereo Targeting (mm)

	A	B	C	D	E	F	
X Value:							Stereo Target
Y Value:							Multi-Pass
Z Value:							Transmit

Pt. Name: YIP

Operator: AL

Comment : POST EXAM MARKER ON

Exp: 1.00

nAs: 80.00

Time: 10:17:05

Mode: 512 F

View: Stereo

Compression: 42.9

Comment :

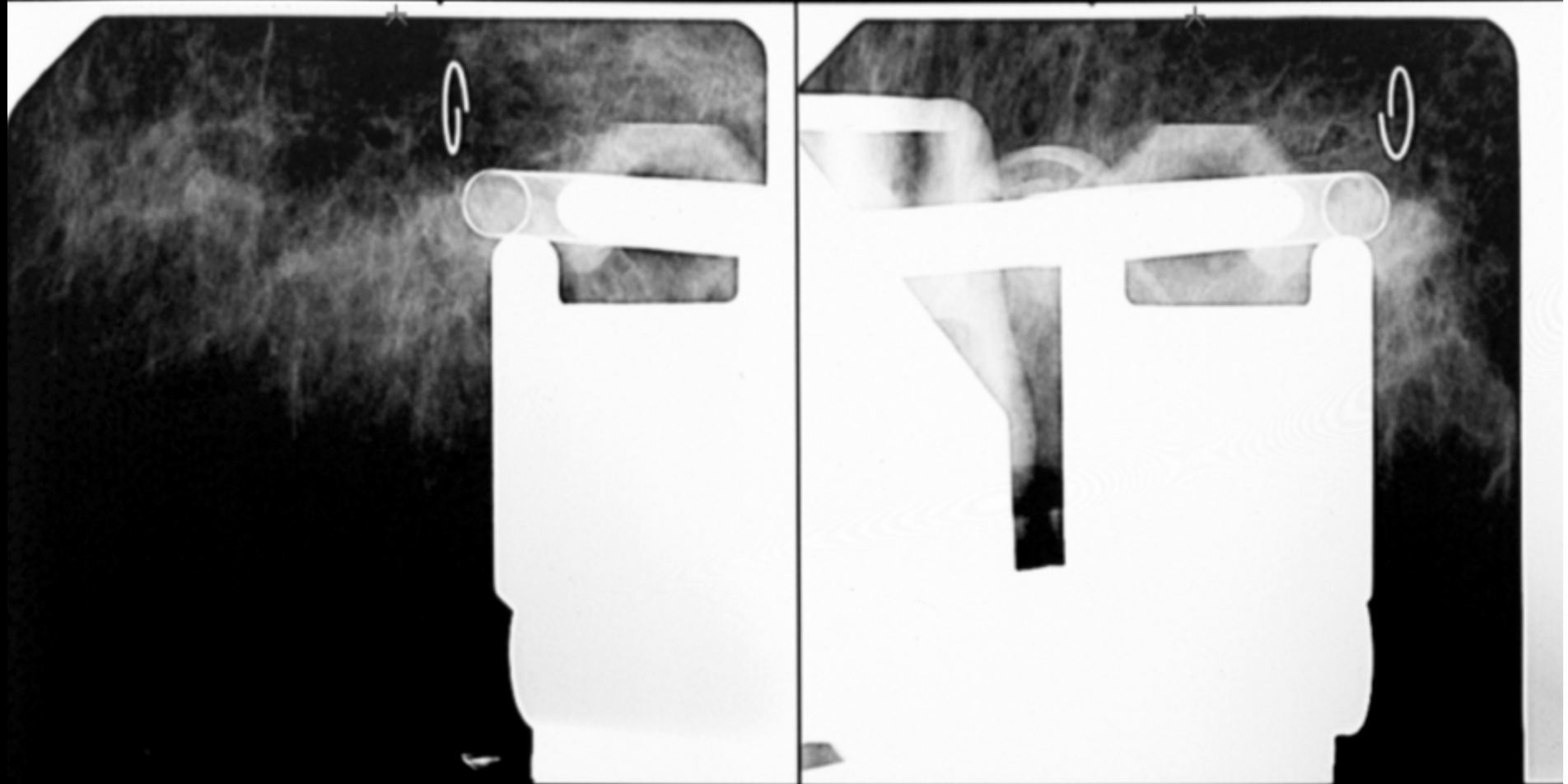
Exp: 1.00

nAs: 80.00

Time: 10:16:47

Mode: 512 F

View: Stereo

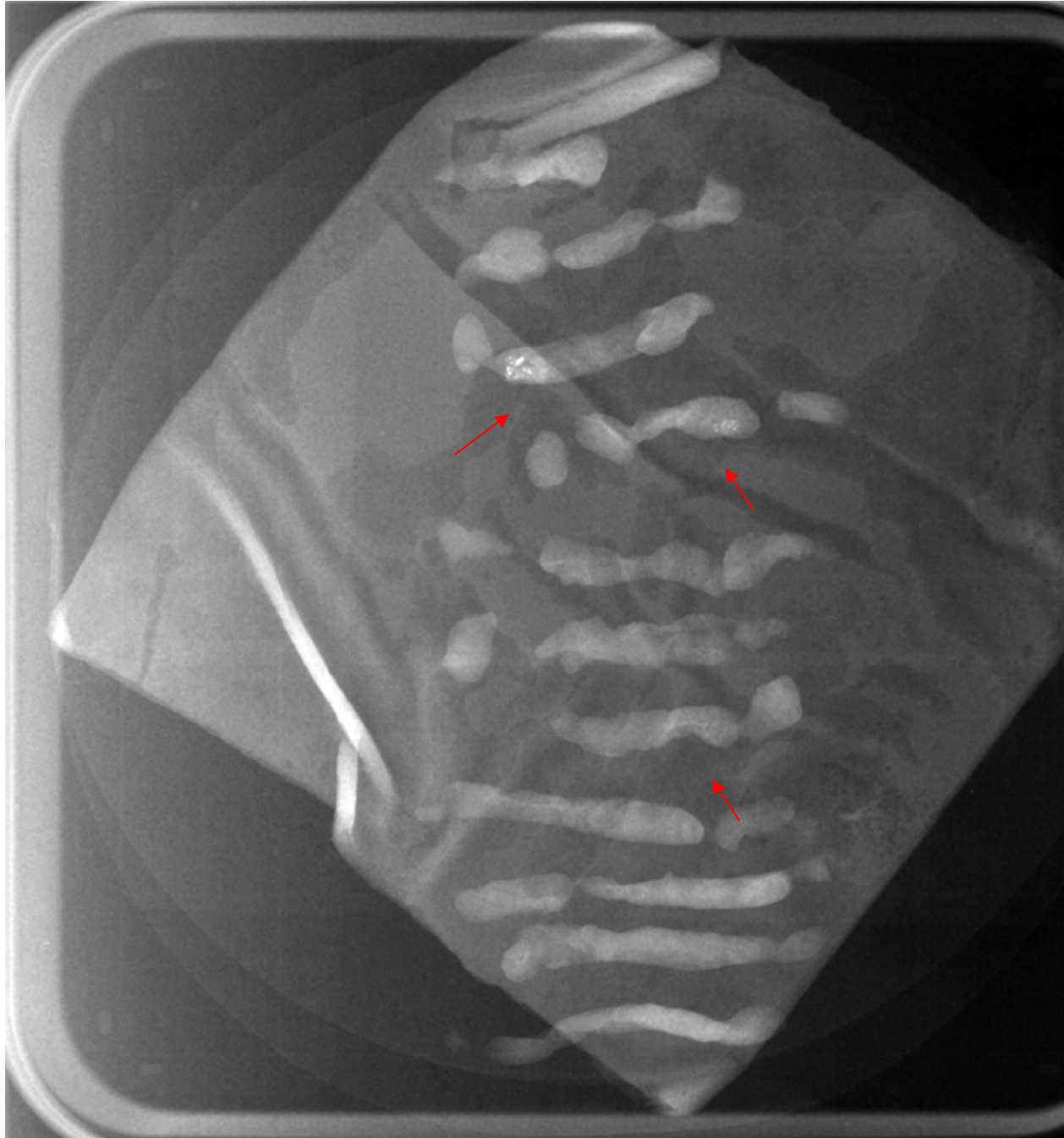


Stereo Targeting [mm]						
	A	B	C	D	E	F
X Value:						
Y Value:						
Z Value:						

Stereo Target

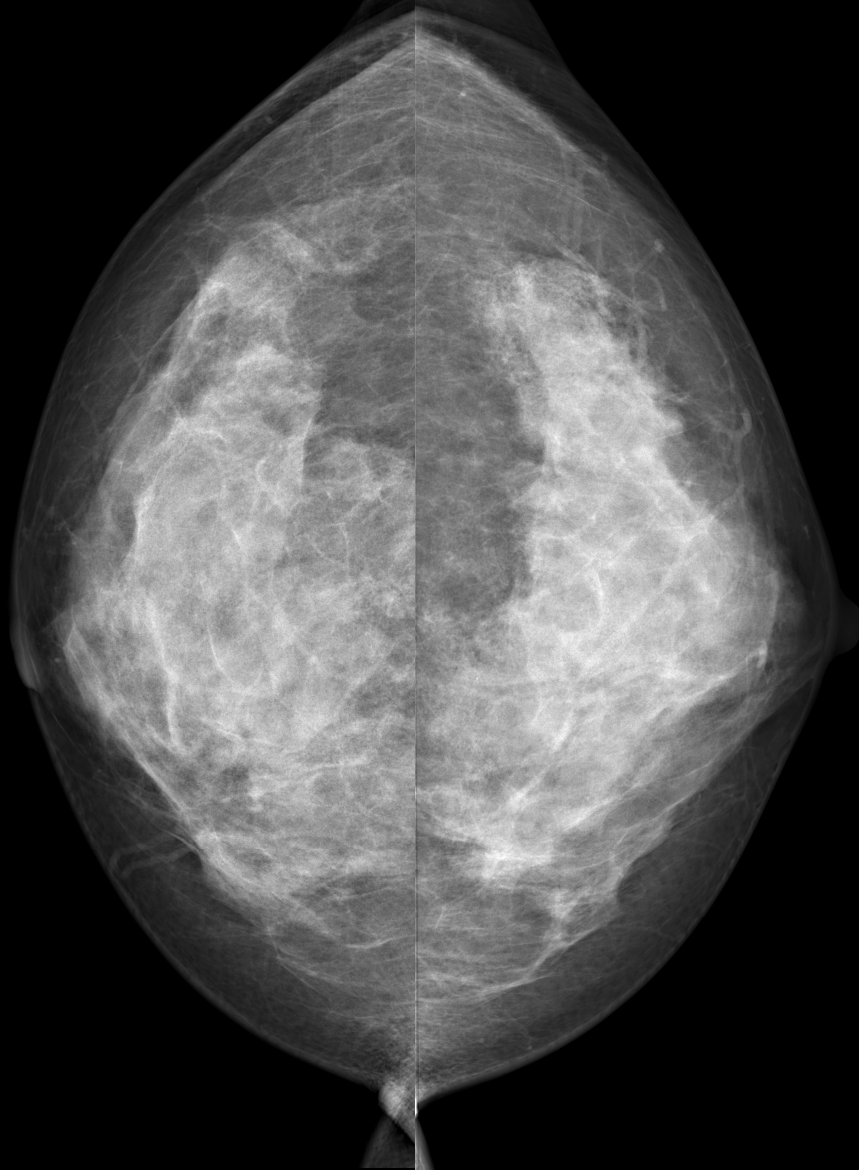
Multi-Pass

Transmit



**52/F BRCA 2**

**Normal mammogram & ultrasound**

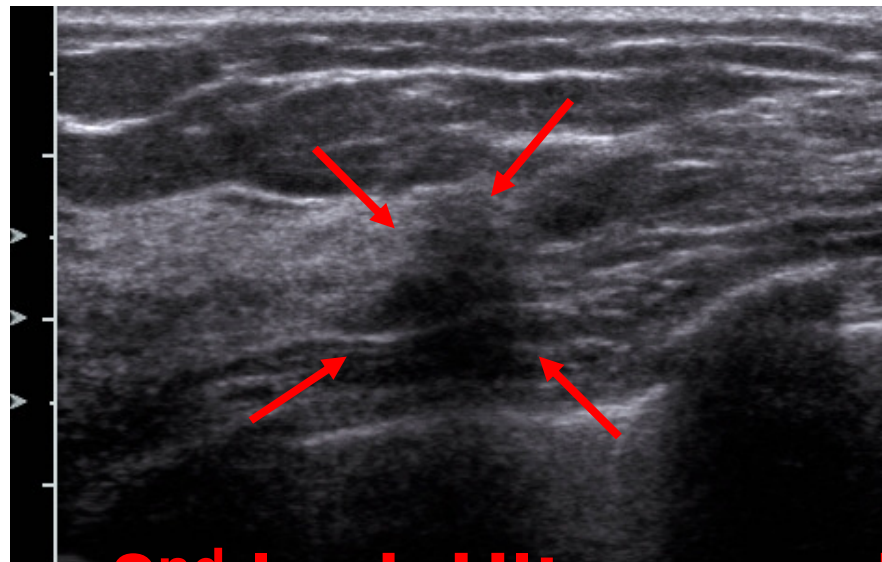
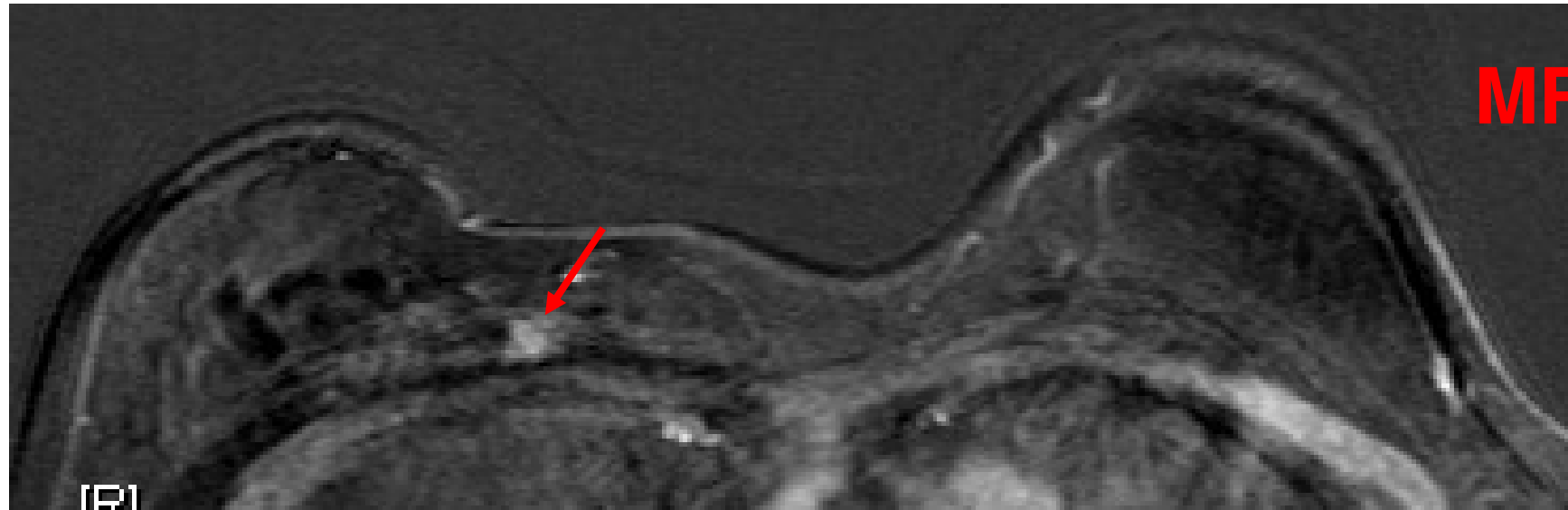


shed ("HighContrast")

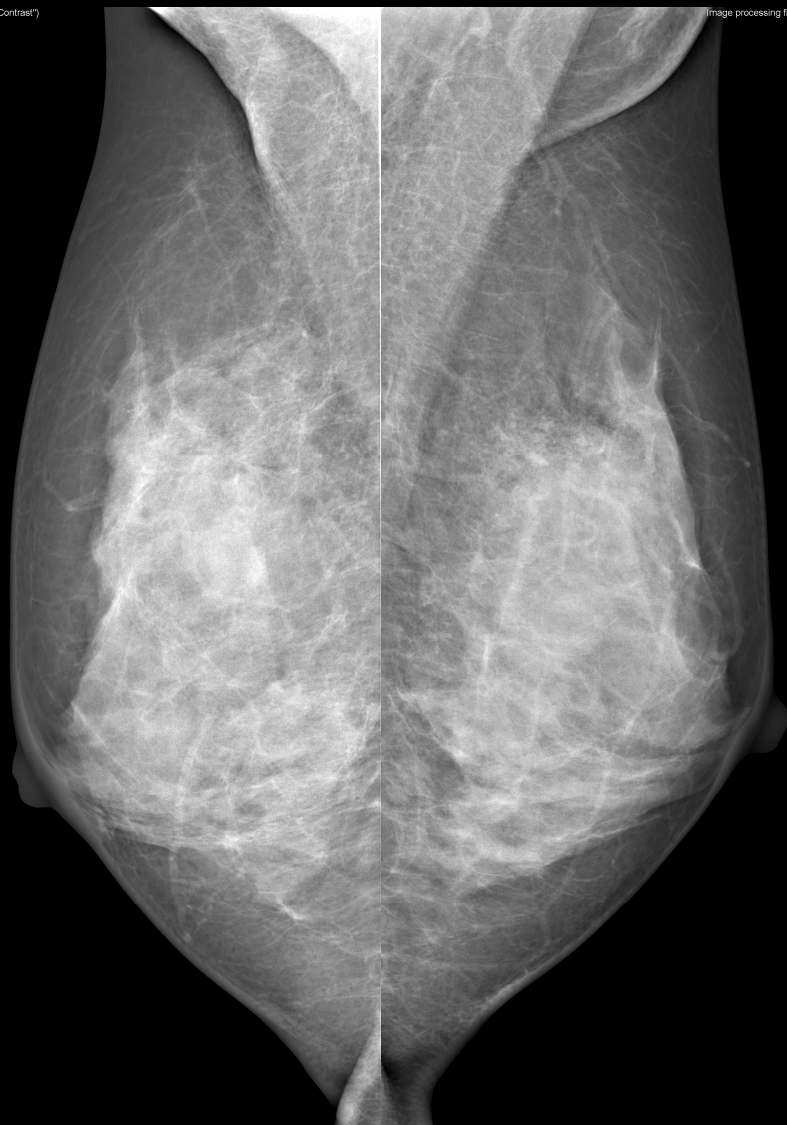

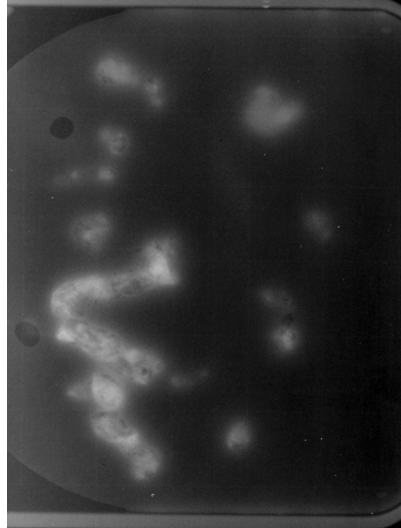
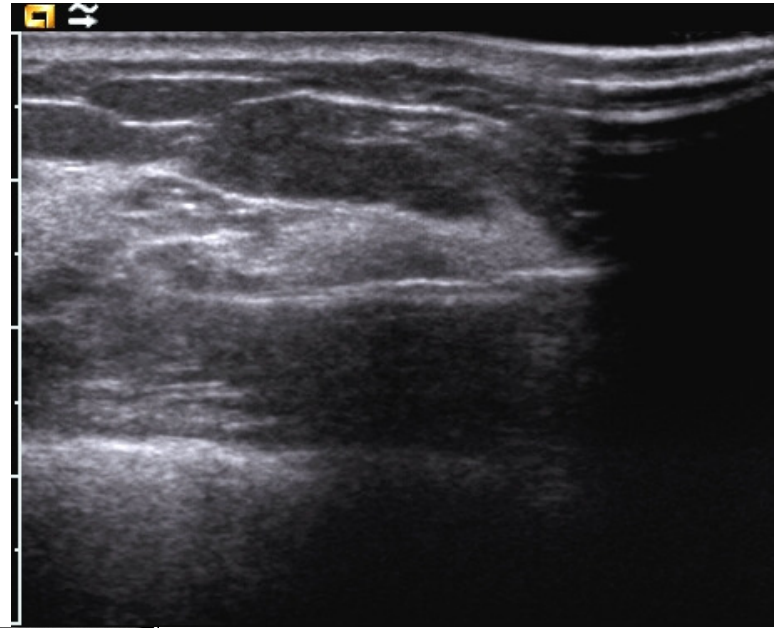
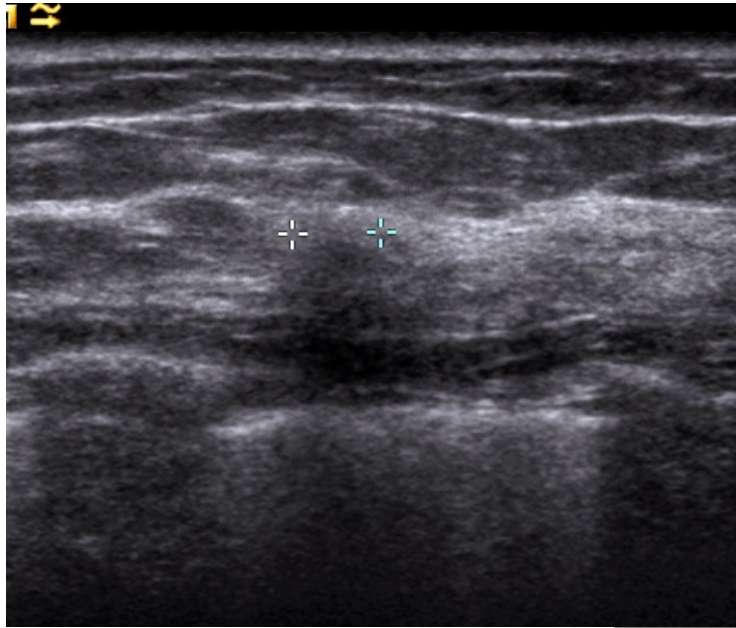
Image processing finished ("HighC

**52/F BRCA 2, an enhancing lesion at 2:00 (DCIS)**



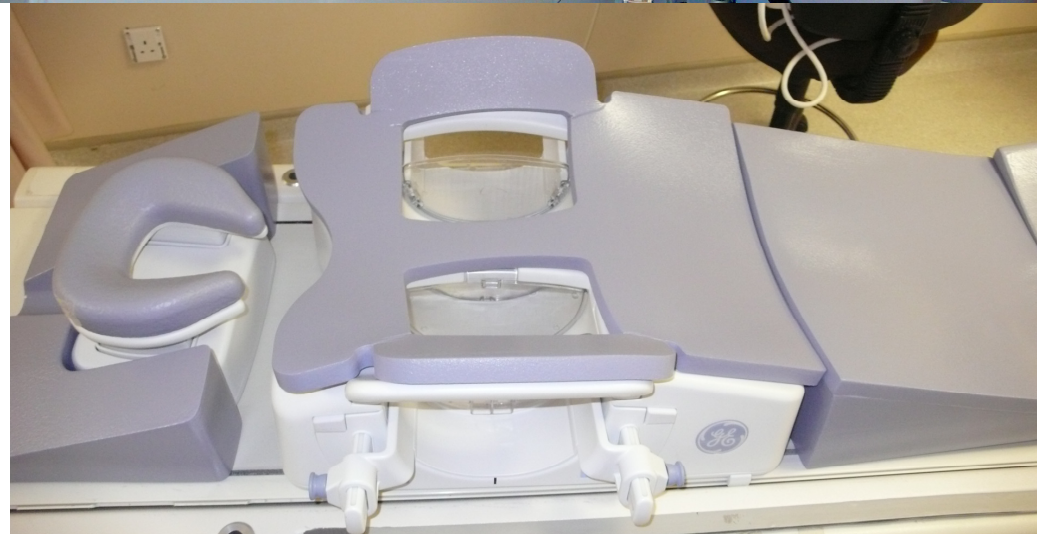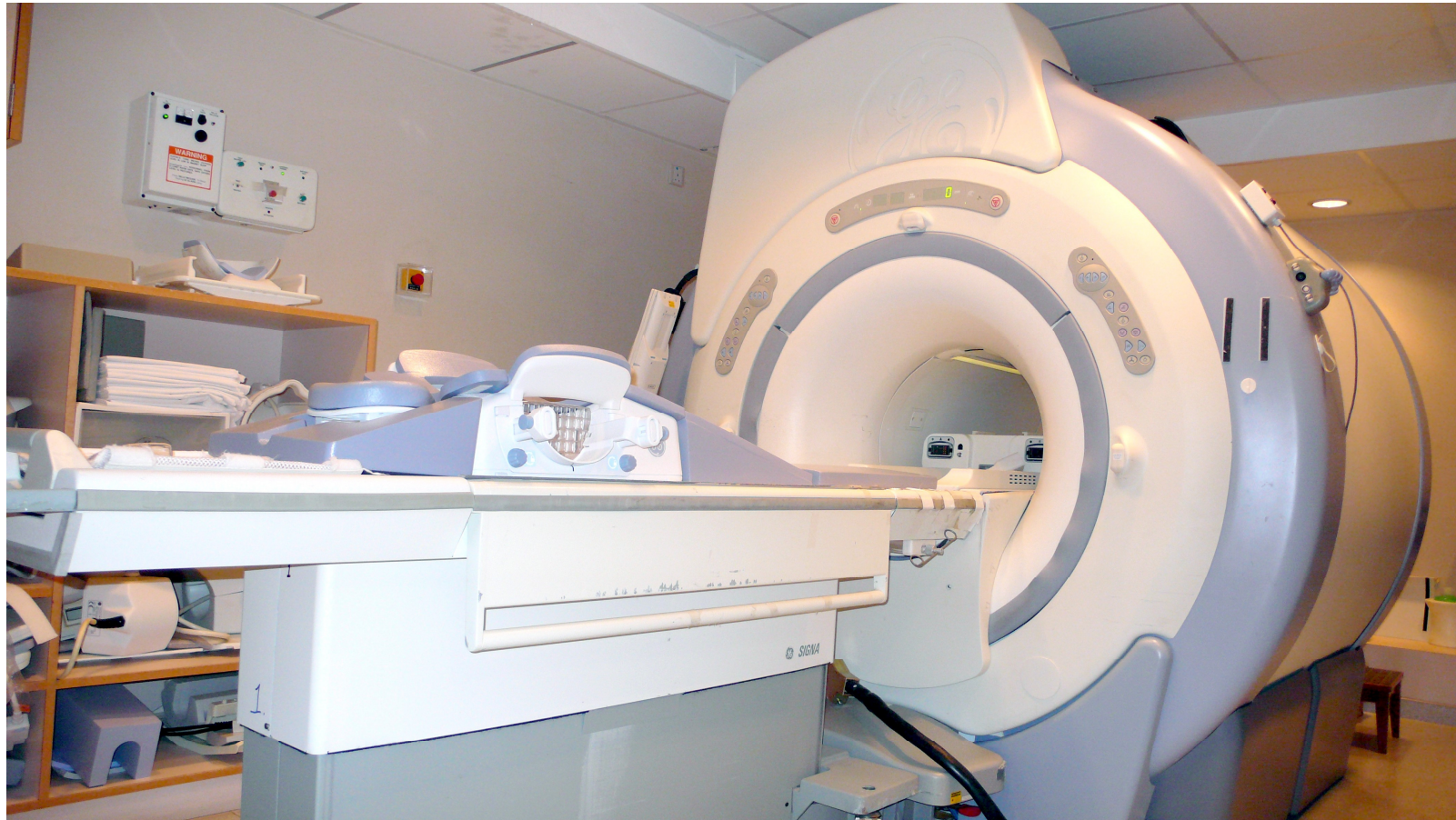
**2<sup>nd</sup> look Ultrasound**

# US guided Vacuum Assisted Breast Bx




**Specimen**

# **MR Guided Breast Intervention**



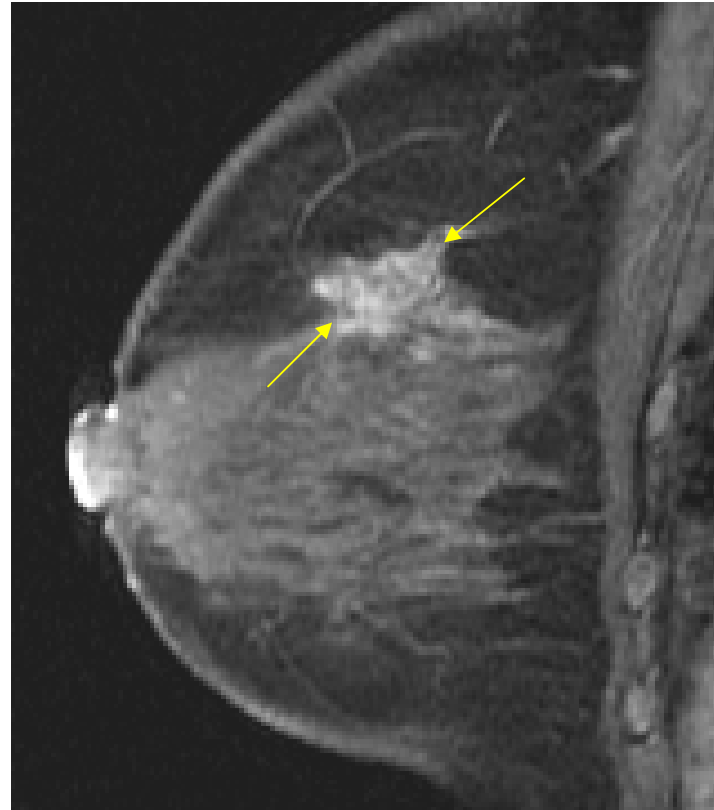
# NR Guided Needle Localization

# Needle with Guidewire

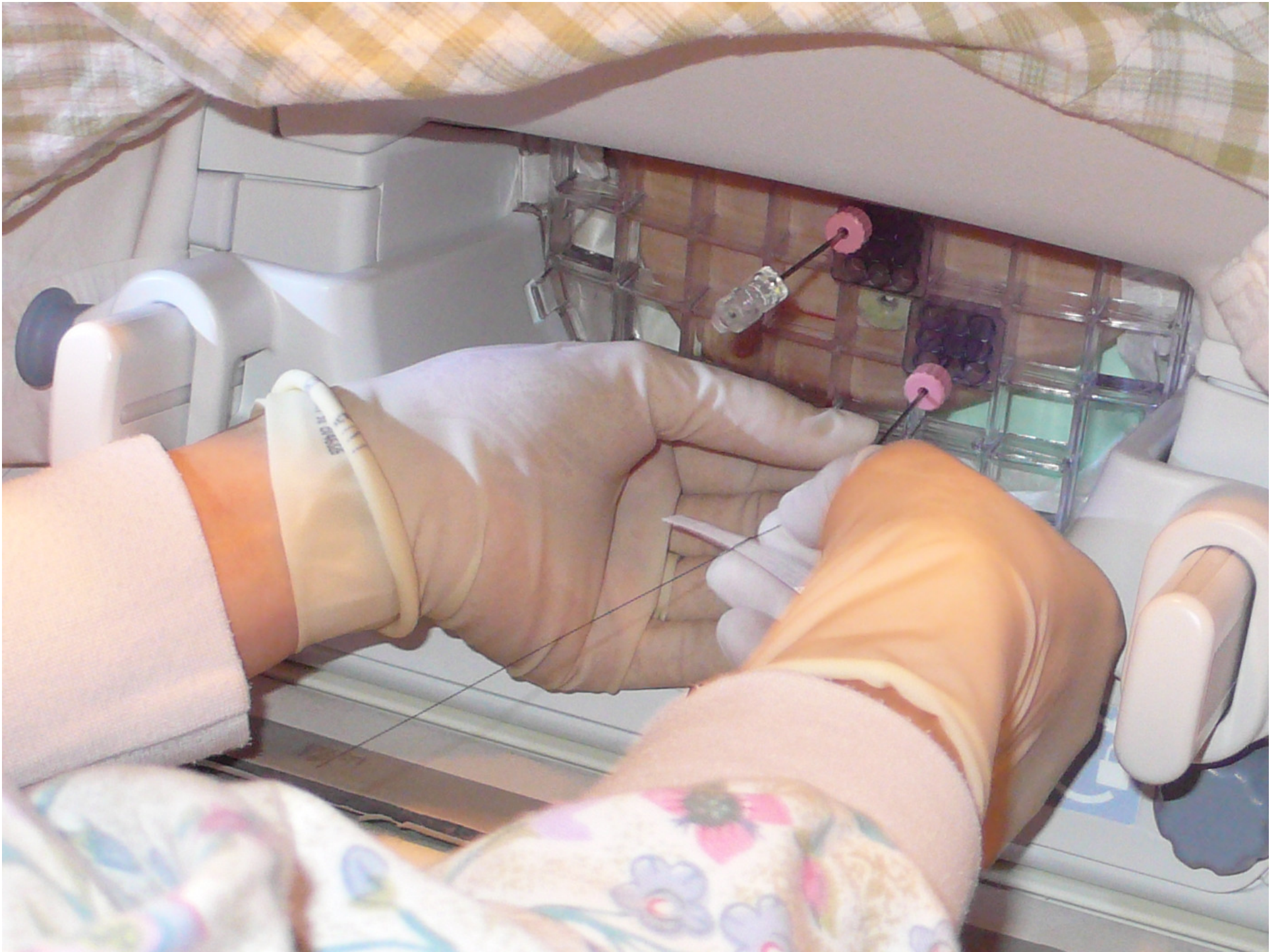


# MRI guided Needle Localization

## 53 F with DCIS from CNB







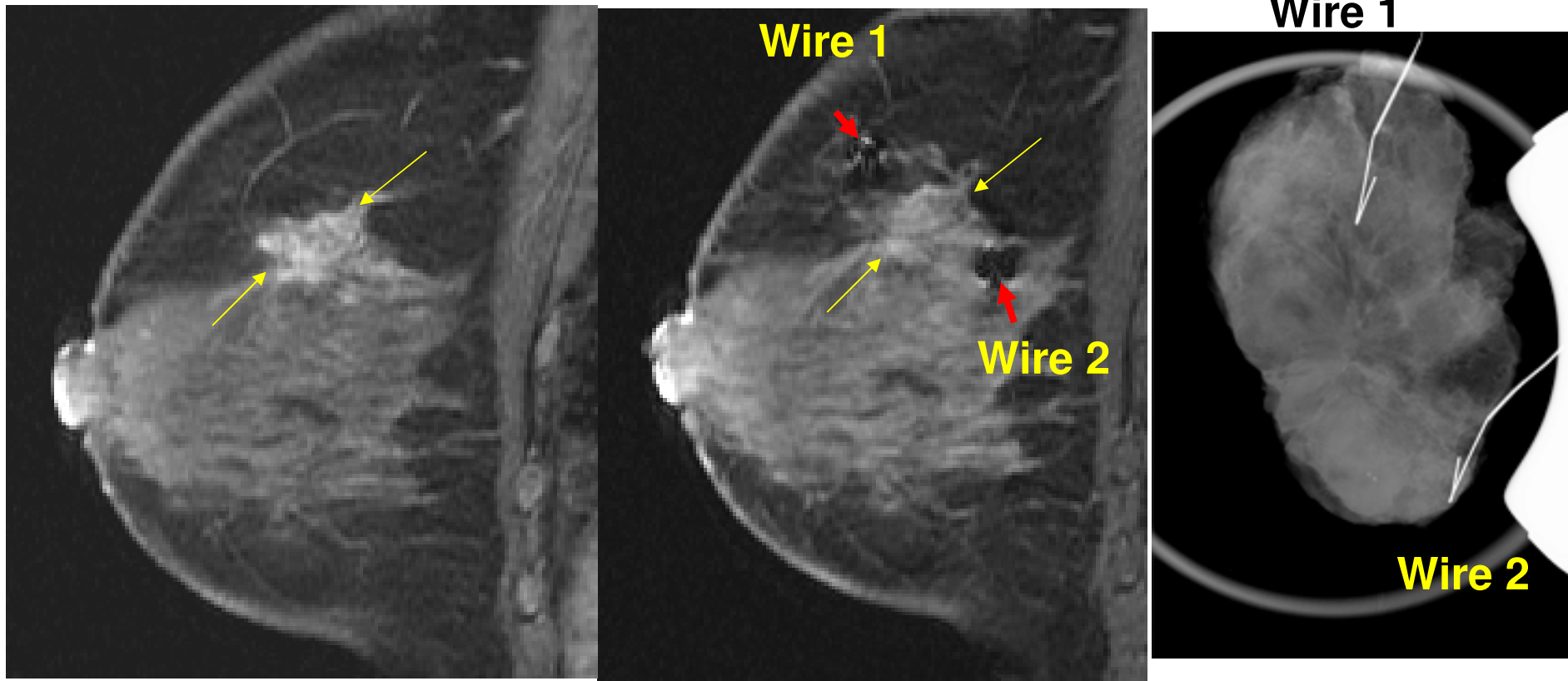


Wire 1

Wire 2

# MRI guided Needle Localization

## 53 F with DCIS from CNB




**Radial scar  
& DCIS**

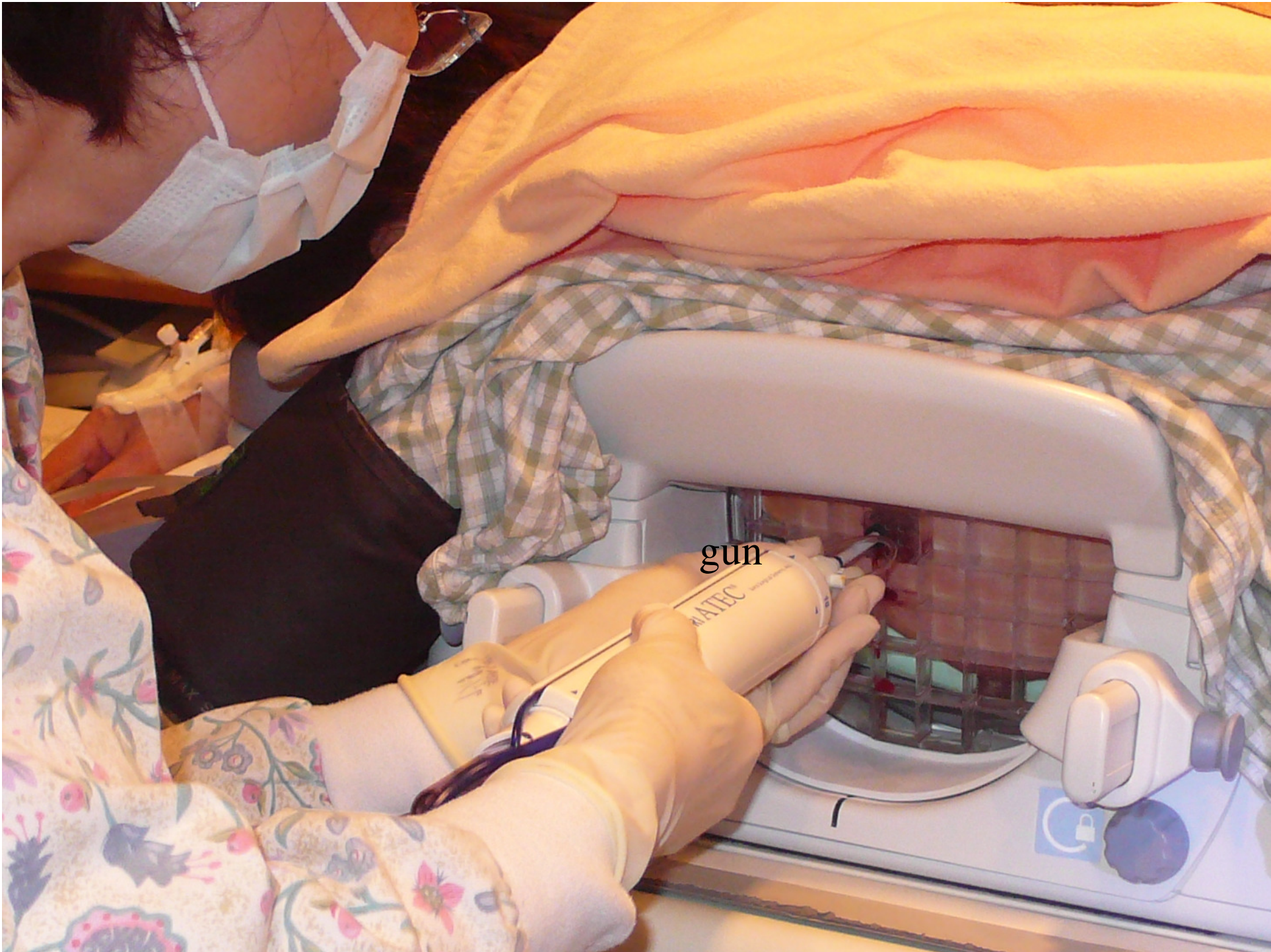# MR Guided Biopsy Methods

- Fine needle aspiration (FNA) 針吸活組織檢查
- Core needle biopsy (CNB) 中心（針吸）活組織檢查
- Vacuum-assisted biopsy (VAB) 真空輔助活檢

# VAB needle: 10-12 Gauge

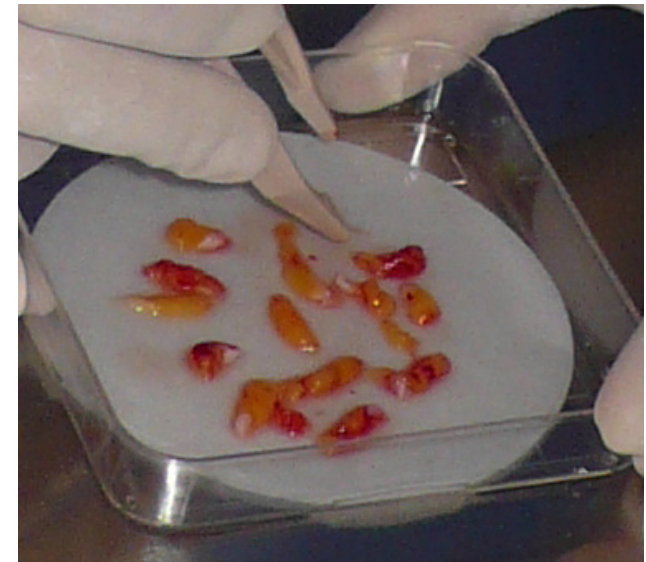
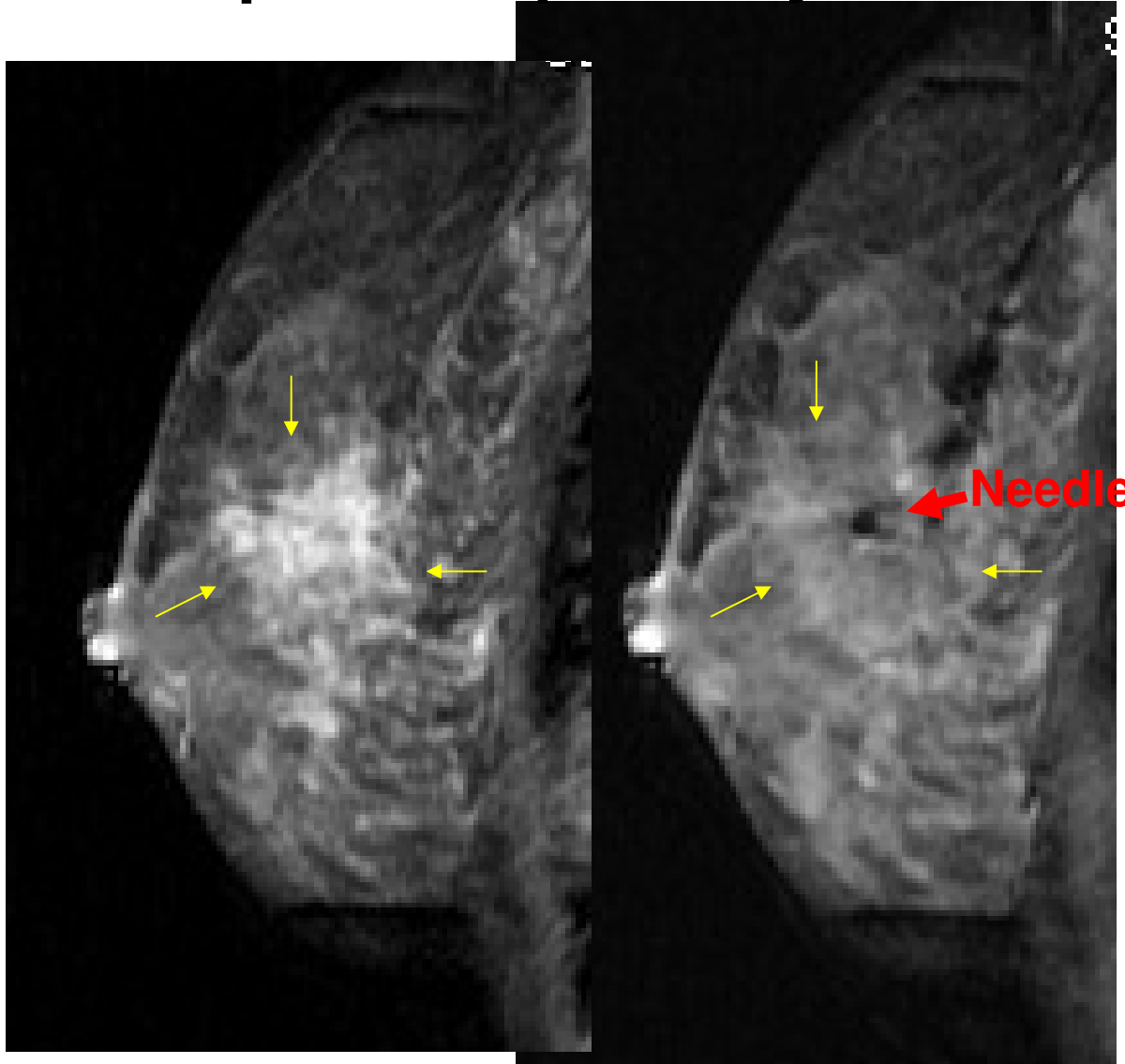






# Vaccum Assisted Breast Bx (DCIS)

47 F post-lumpectomy for CA breast 1 month ago



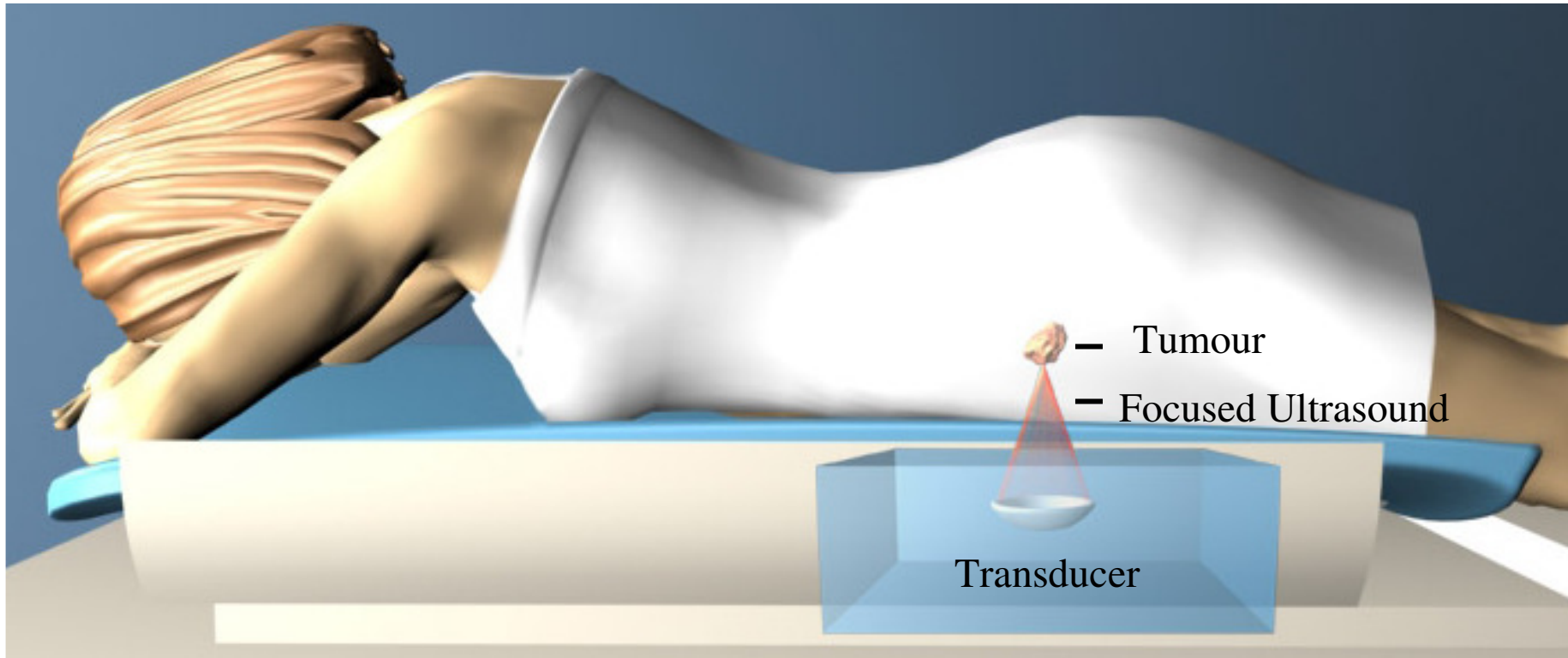
**specimen**

# Uterine fibroid management

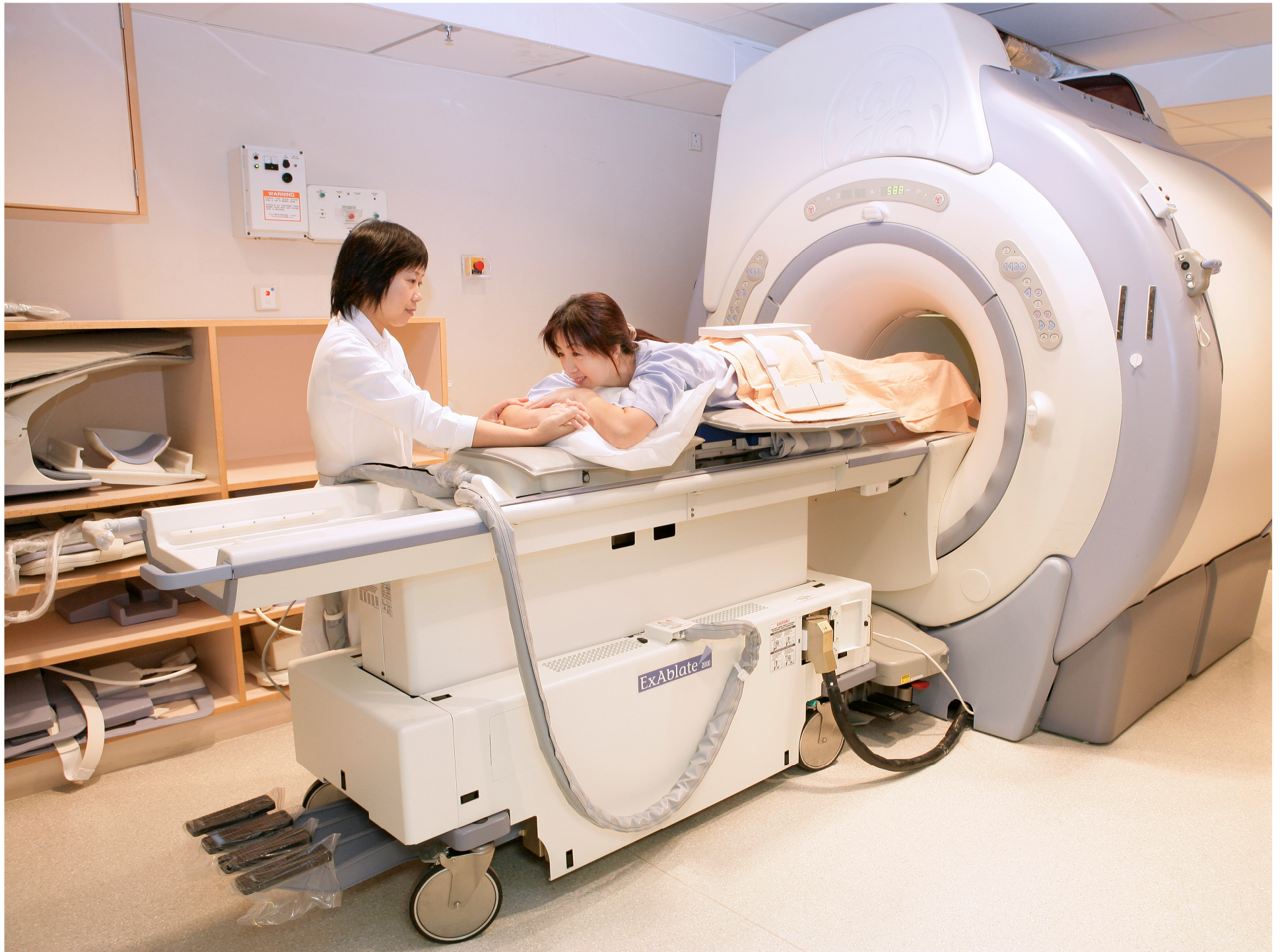- 1) Surgical resection (invasive)
- 2) Minimal invasive: Uterine artery  
Embolization.
- 3) Non-invasive: Focus ultrasound  
聚焦超声外科

# Focused Ultrasound (FUS)

## 聚焦超声外科



Focused ultrasound generates heat, ablating tissue only at the focal point. The effect is similar to a magnifying glass used to focus the sun's energy on a single point



# Vascular Intervention

## 1) Embolotherapy

- Pre-operative embolization
- Bleeding control
- Portal vein embolization

## 2) Stenting

## 3) Miscellaneous

IVC filter

Port-A or Hickman catheter insertion

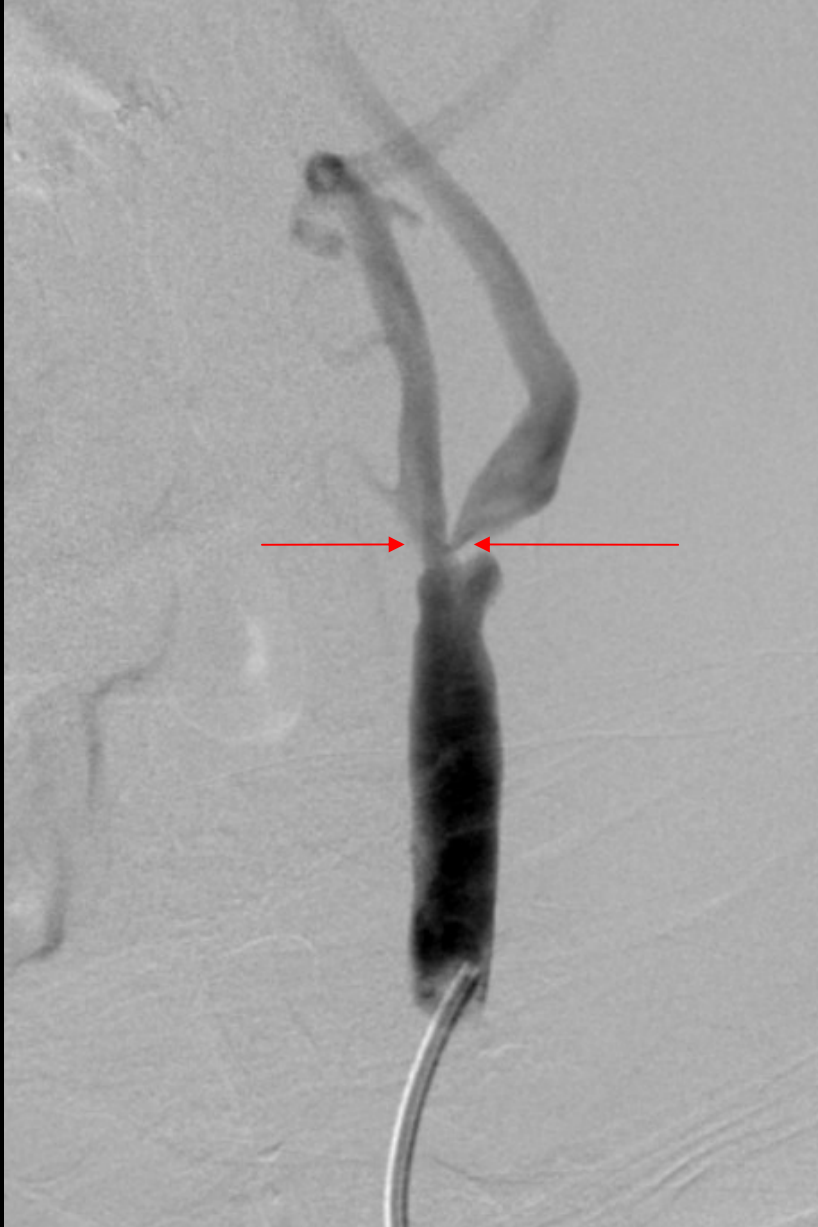Venous sampling

# Stenting Procedure

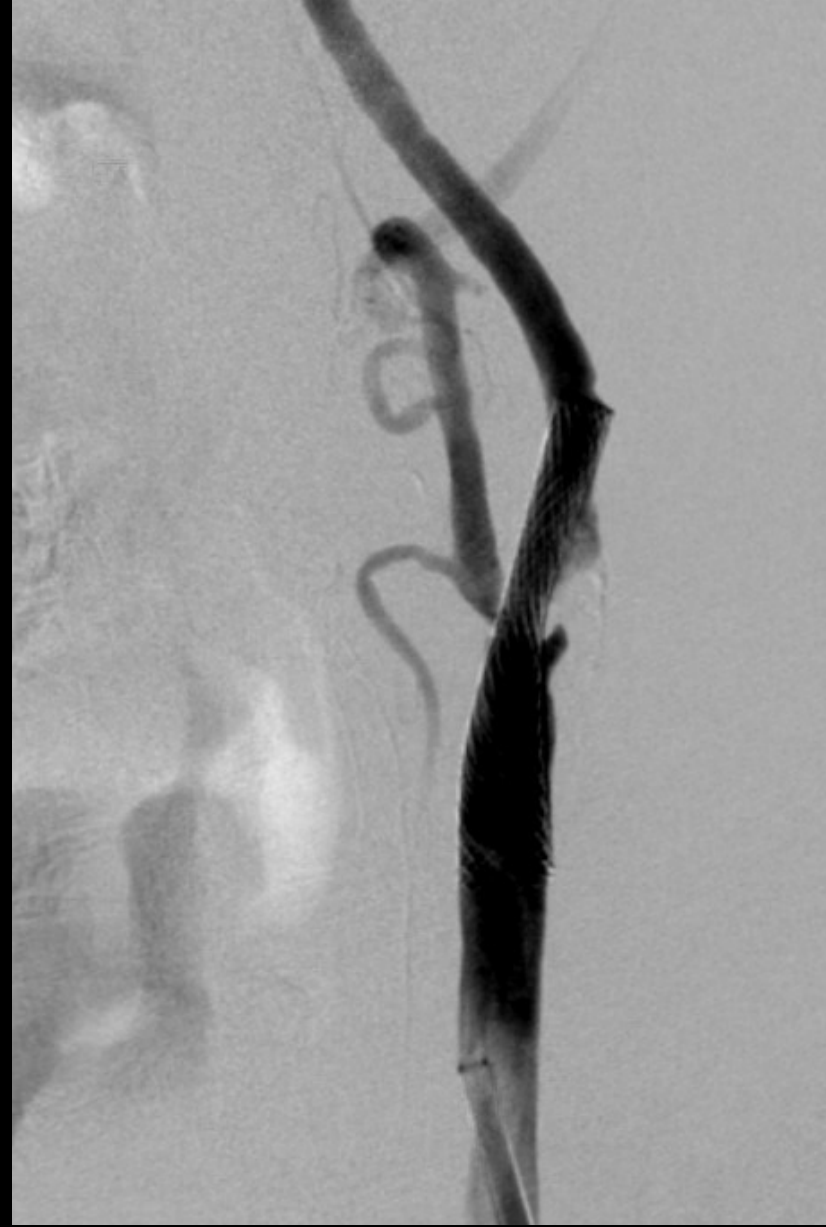- Video

# Carotid Stenting

- NPC Post-RT patient - not suitable for surgery
- Atherosclerosis



**Tight stenosis**



**Post-stenting**

# Post-treatment, complication management

SVC stenting

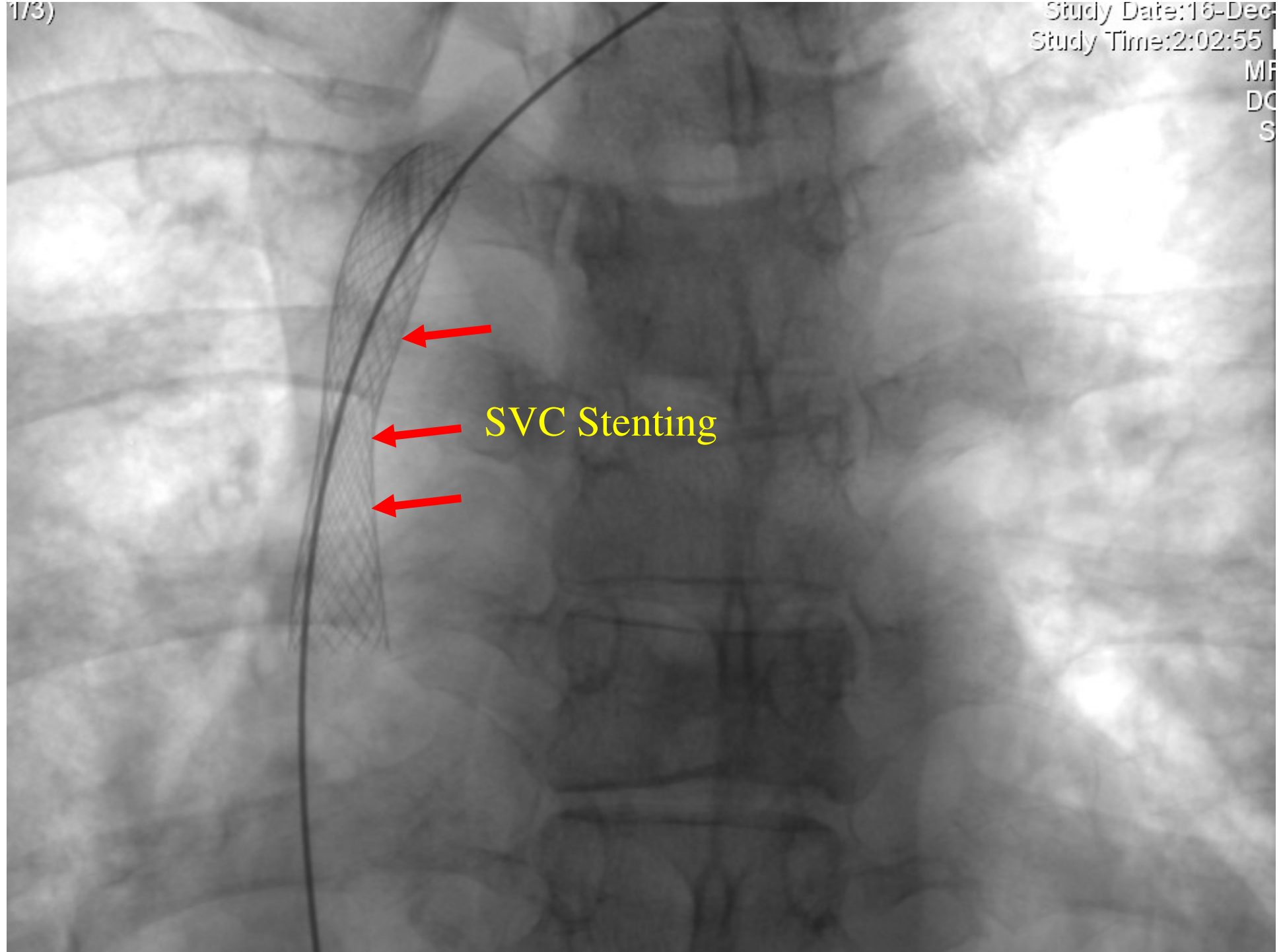
Post-RT severe SVC  
stenosis



[R]

CA lung Patient. Post-Radiotherapy.

Present with facial and upper limb edema.



Im:100 (F2/2)

Study Date:16-Dec-0  
Study Time:2:02:55 P  
MRI  
DOI  
Se

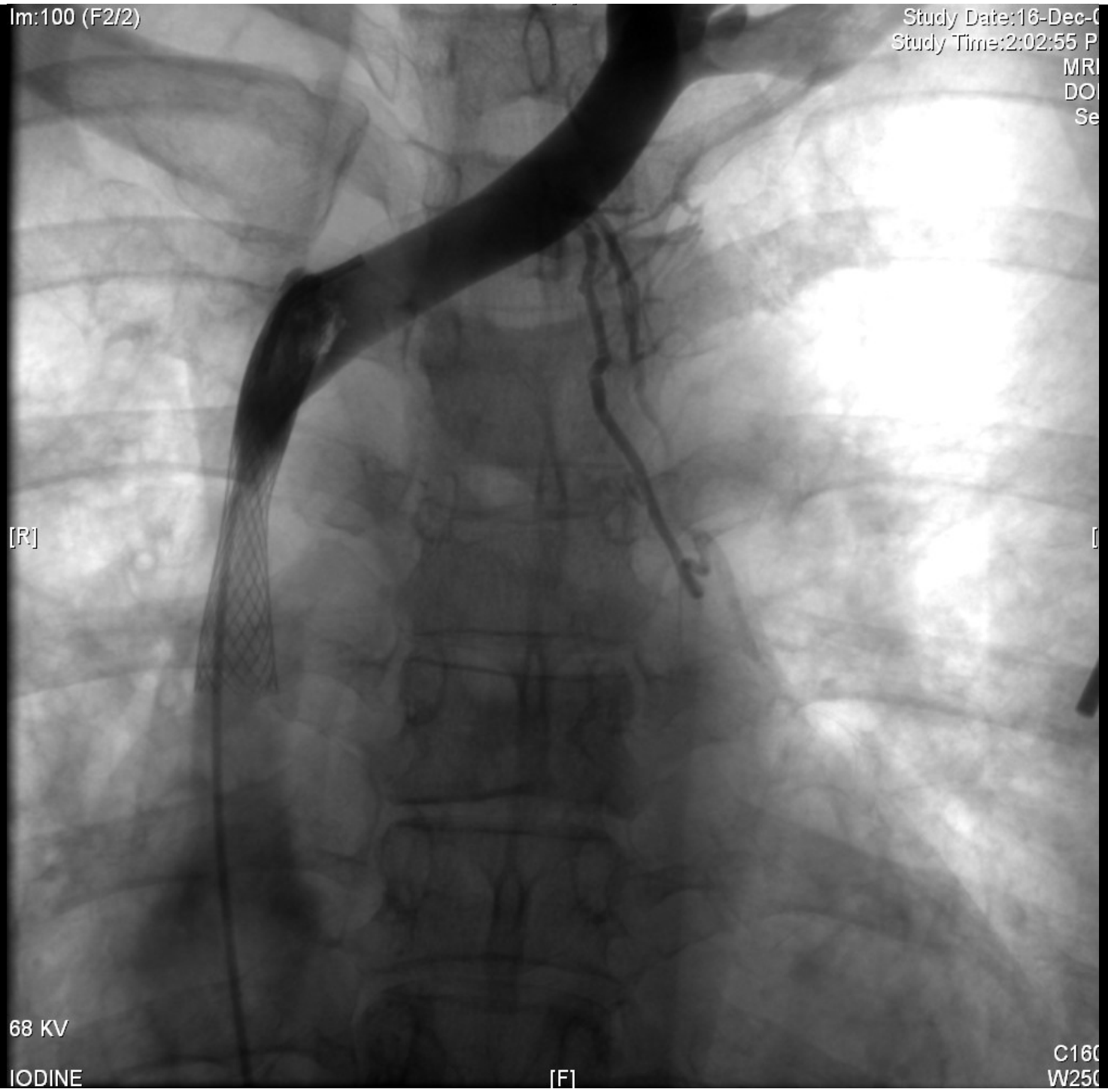[R]

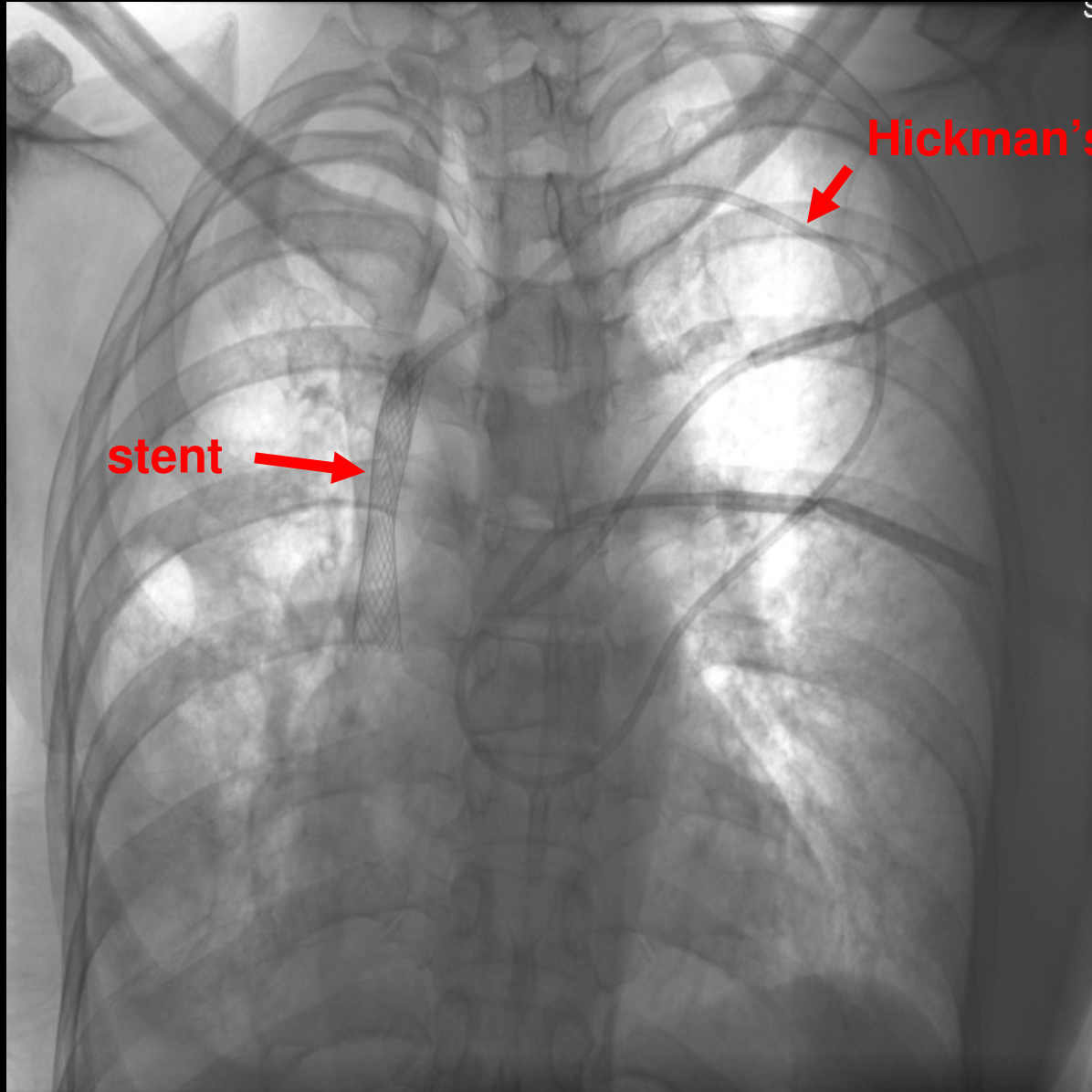
68 KV

IODINE

[F]

C160  
W250





Hickman's catheter

stent

# Embolotherapy

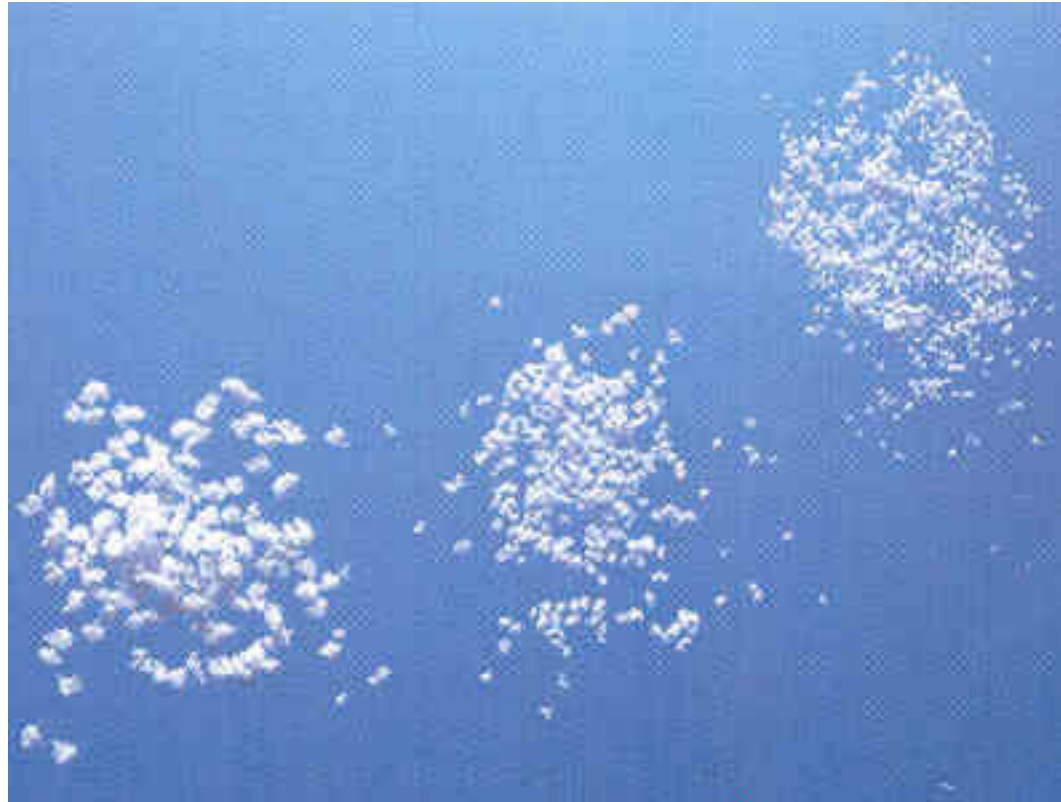栓塞術治療

# Embolization Procedure

Material:

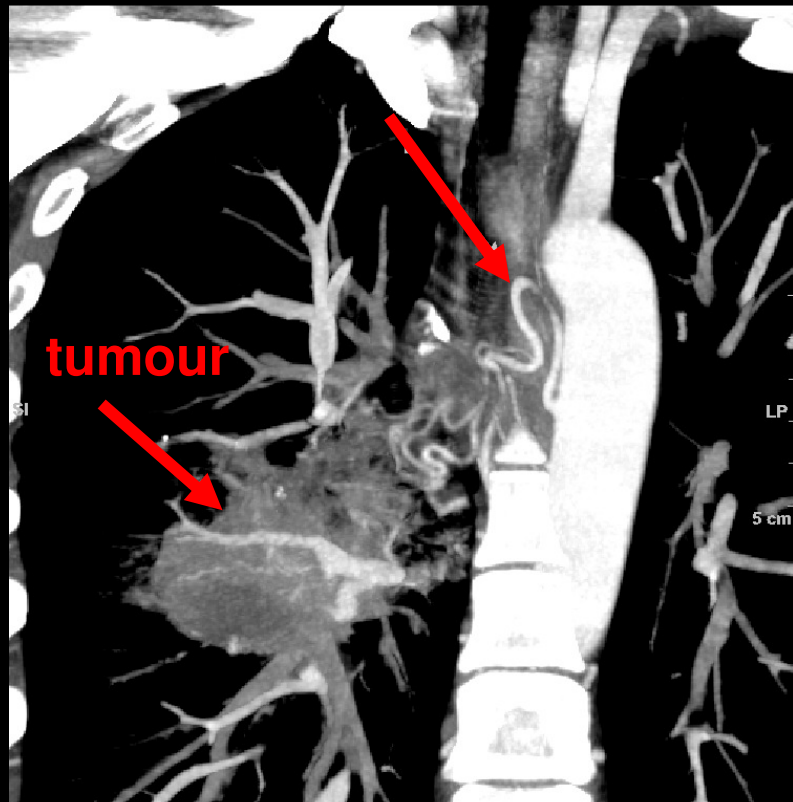
- 1) Gel-foam particle
- 2) Polyvinyl Alcohol (PVA) particle
- 3) Absolute Alcohol
- 4) Metallic Coil

# PVA for embolization



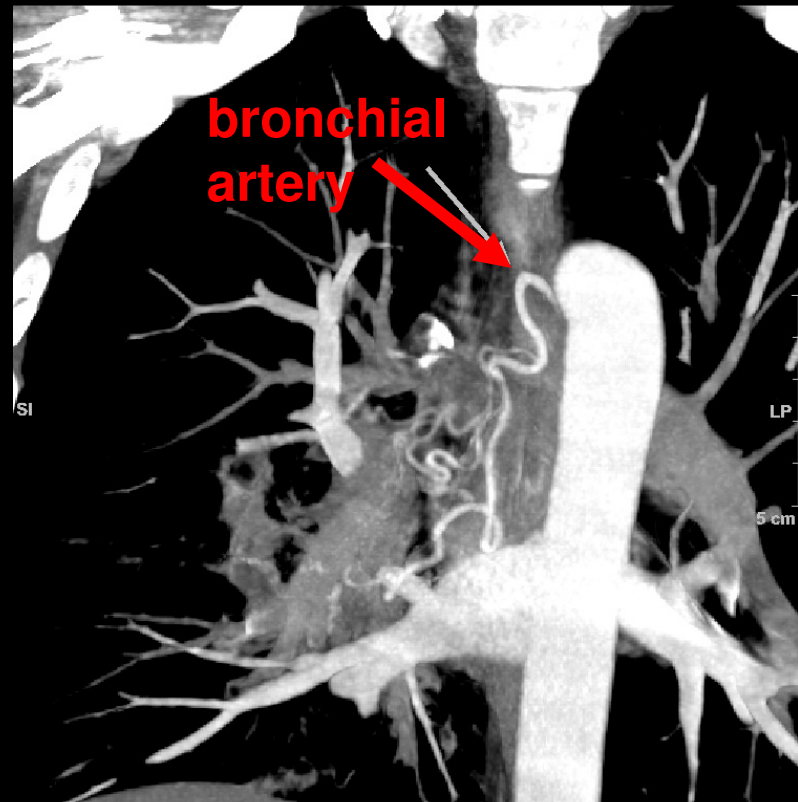
PVA Particles

Se: 104a  
Im: 1

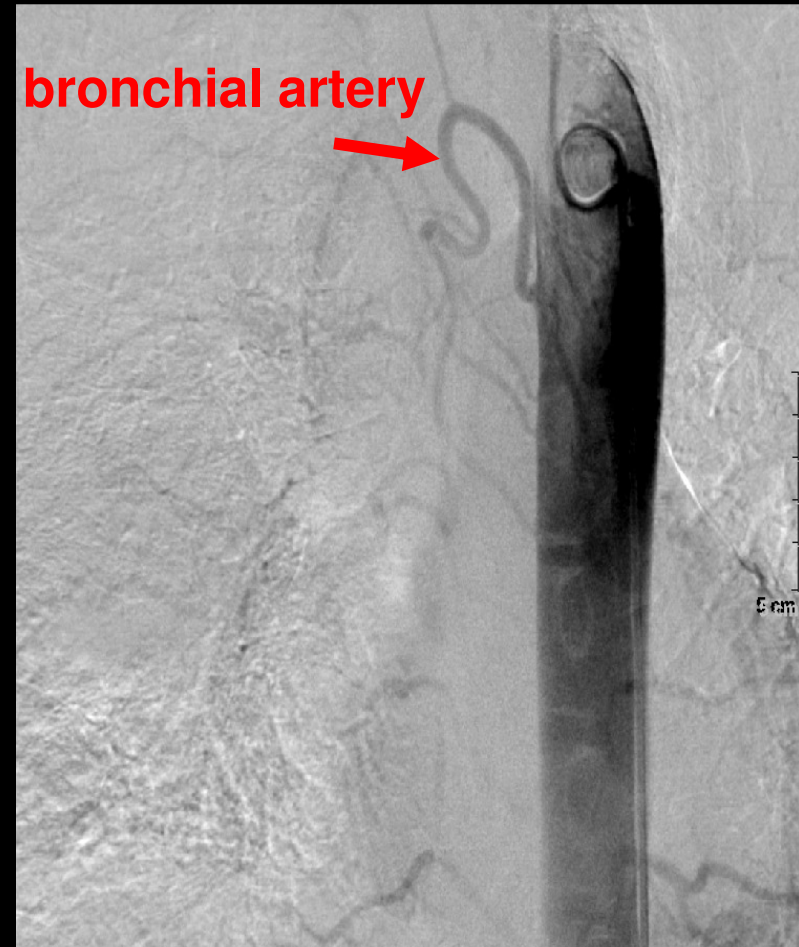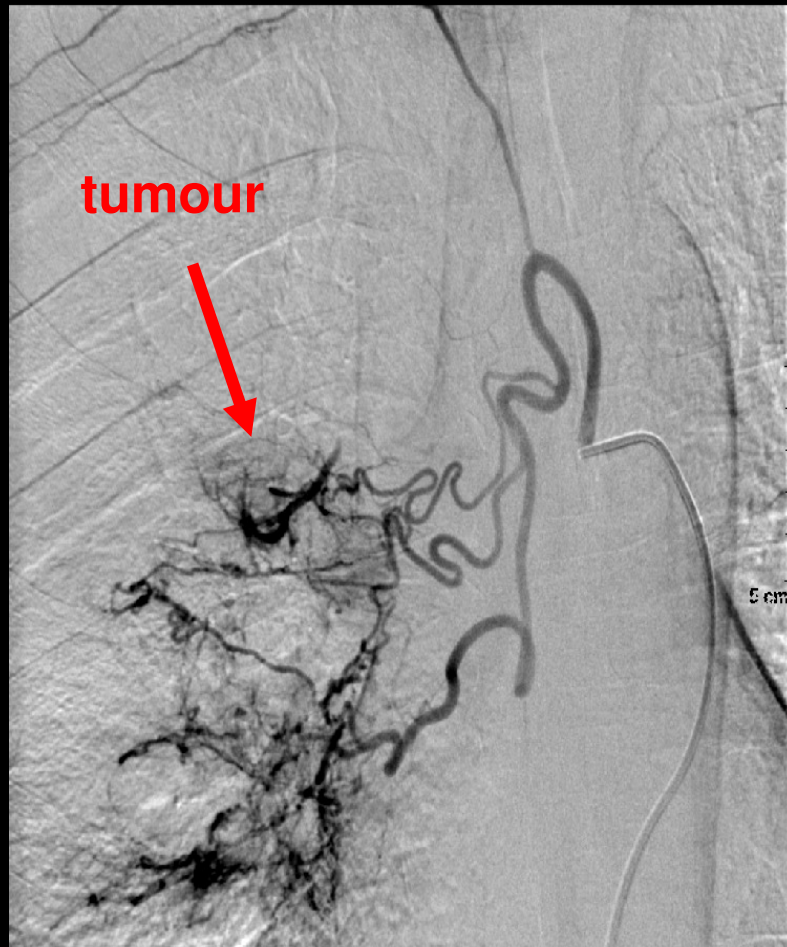


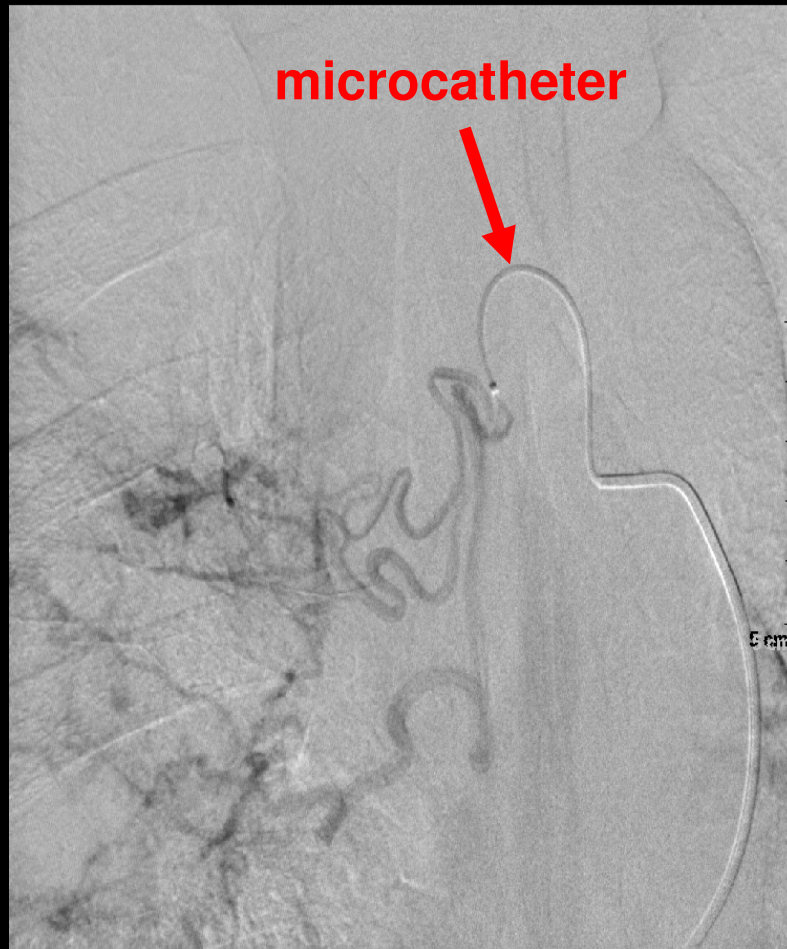
ULT/370 100CC  
FPR  
5 cm  
W: 436  
L: 80

Se: 104a  
Im: 2

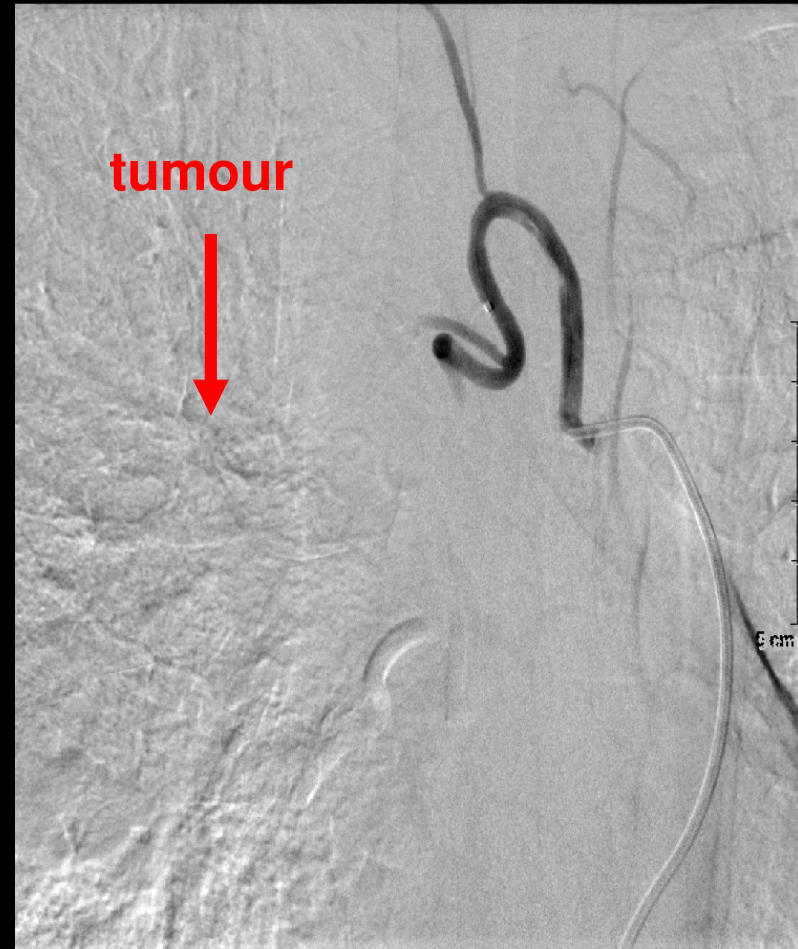


ULT/370 100CC  
F  
5 cm  
W: 436  
L: 80





**Pre-embolisation**



**Post-embolisation**

# Vascular Nasal Tumour

## Pre-operative embolization

Im:304 (F1/1)

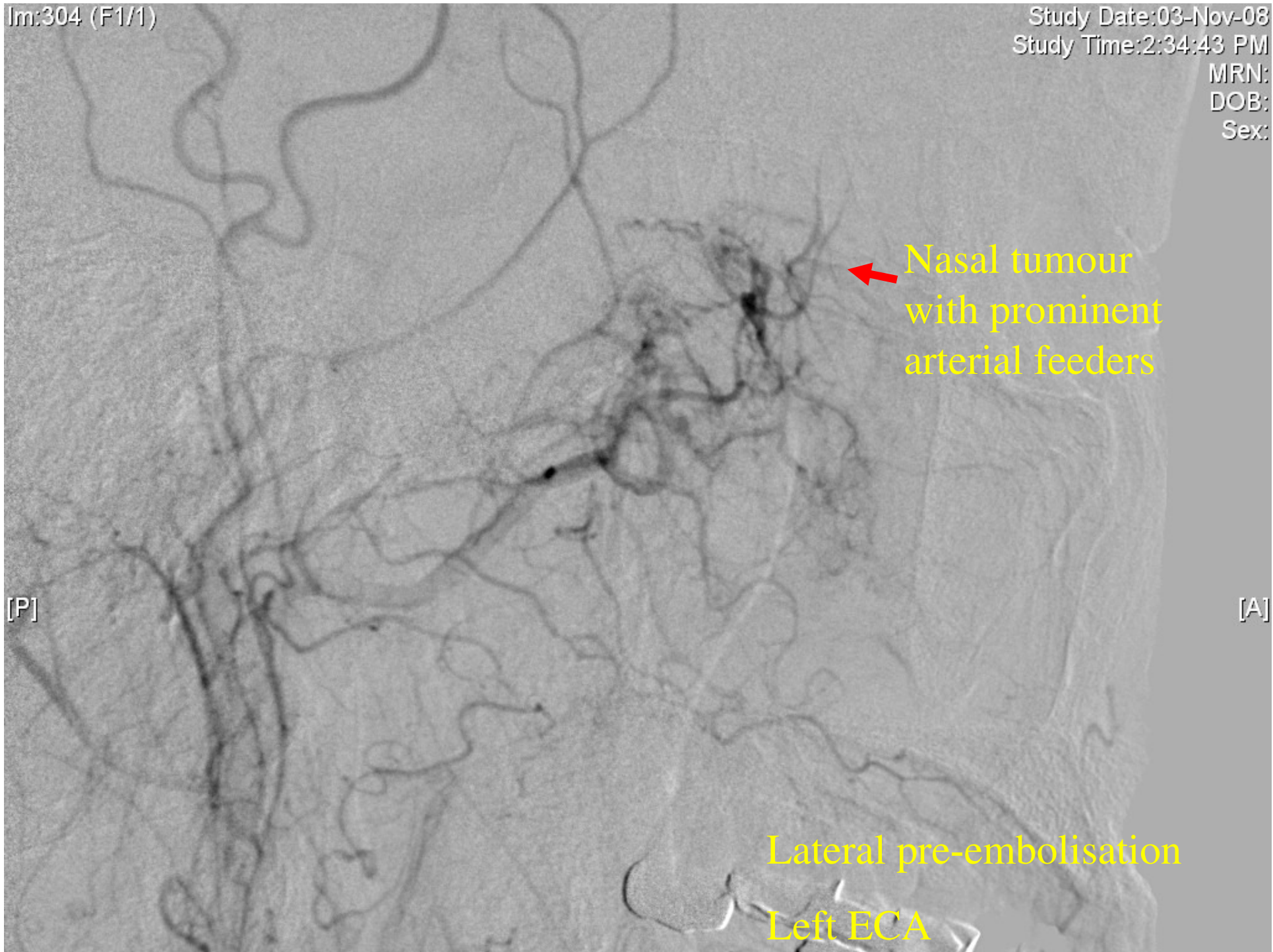
Study Date:03-Nov-08  
Study Time:2:34:43 PM  
MRN:  
DOB:  
Sex:

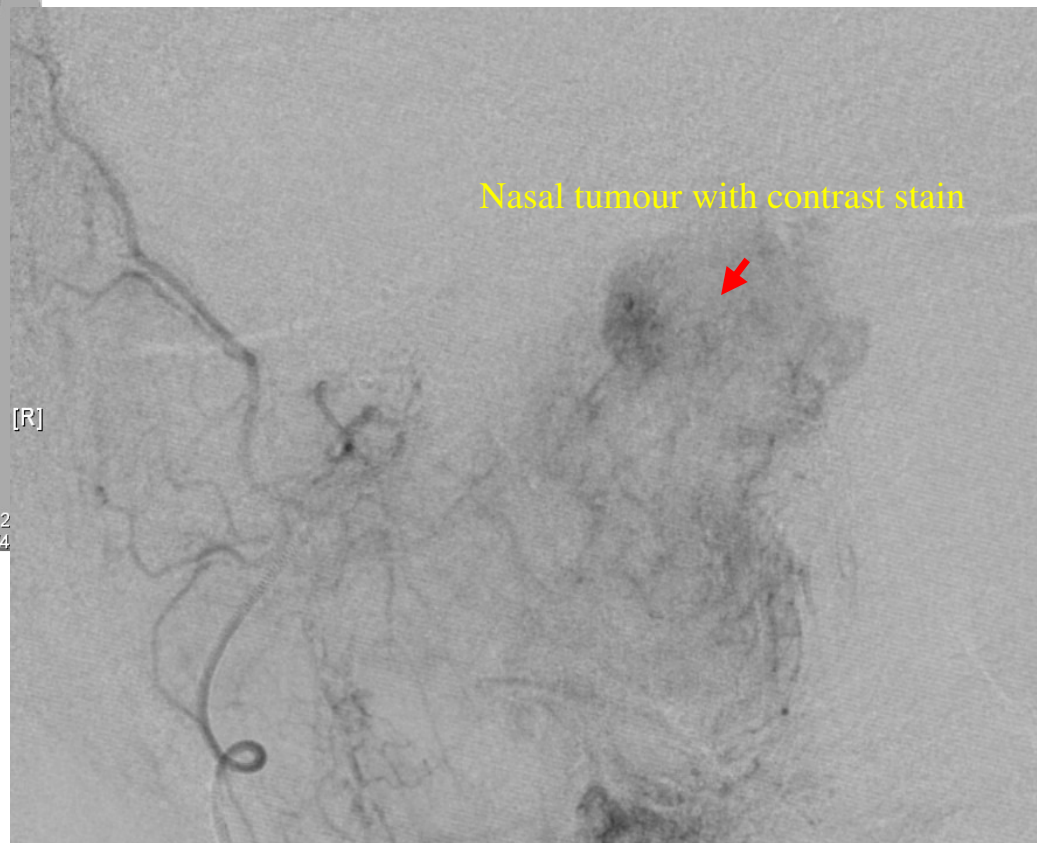
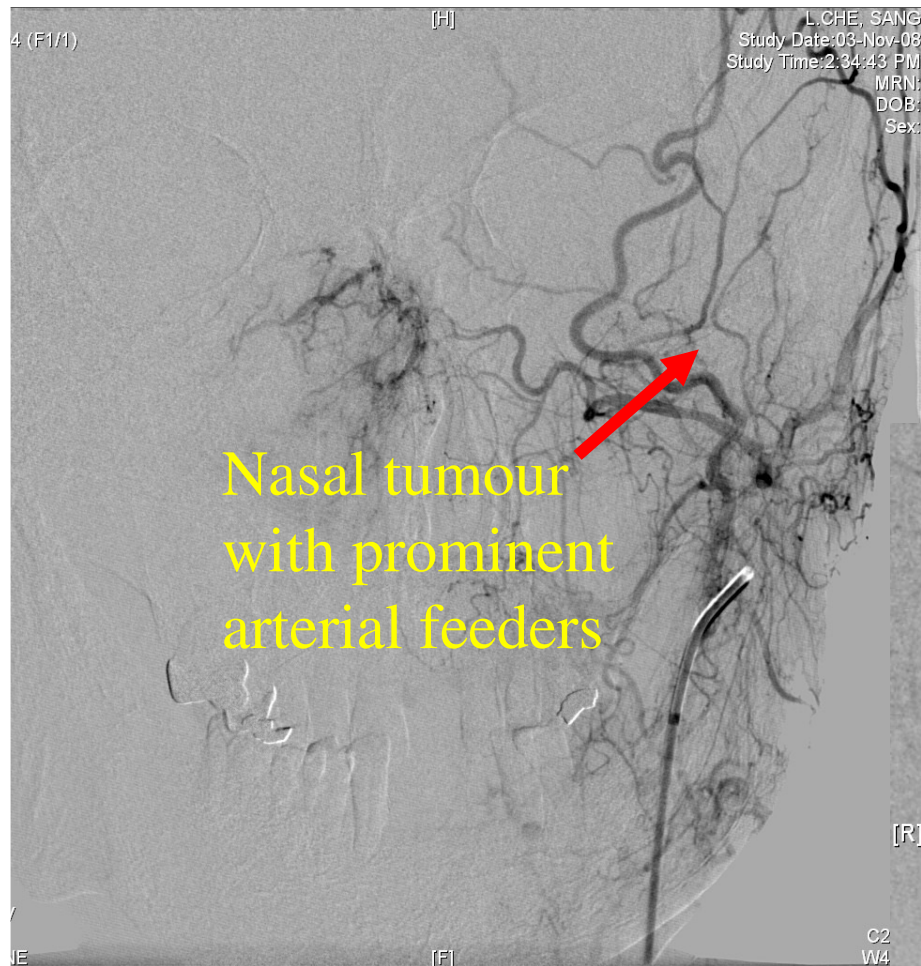
← Nasal tumour  
with prominent  
arterial feeders

[P]

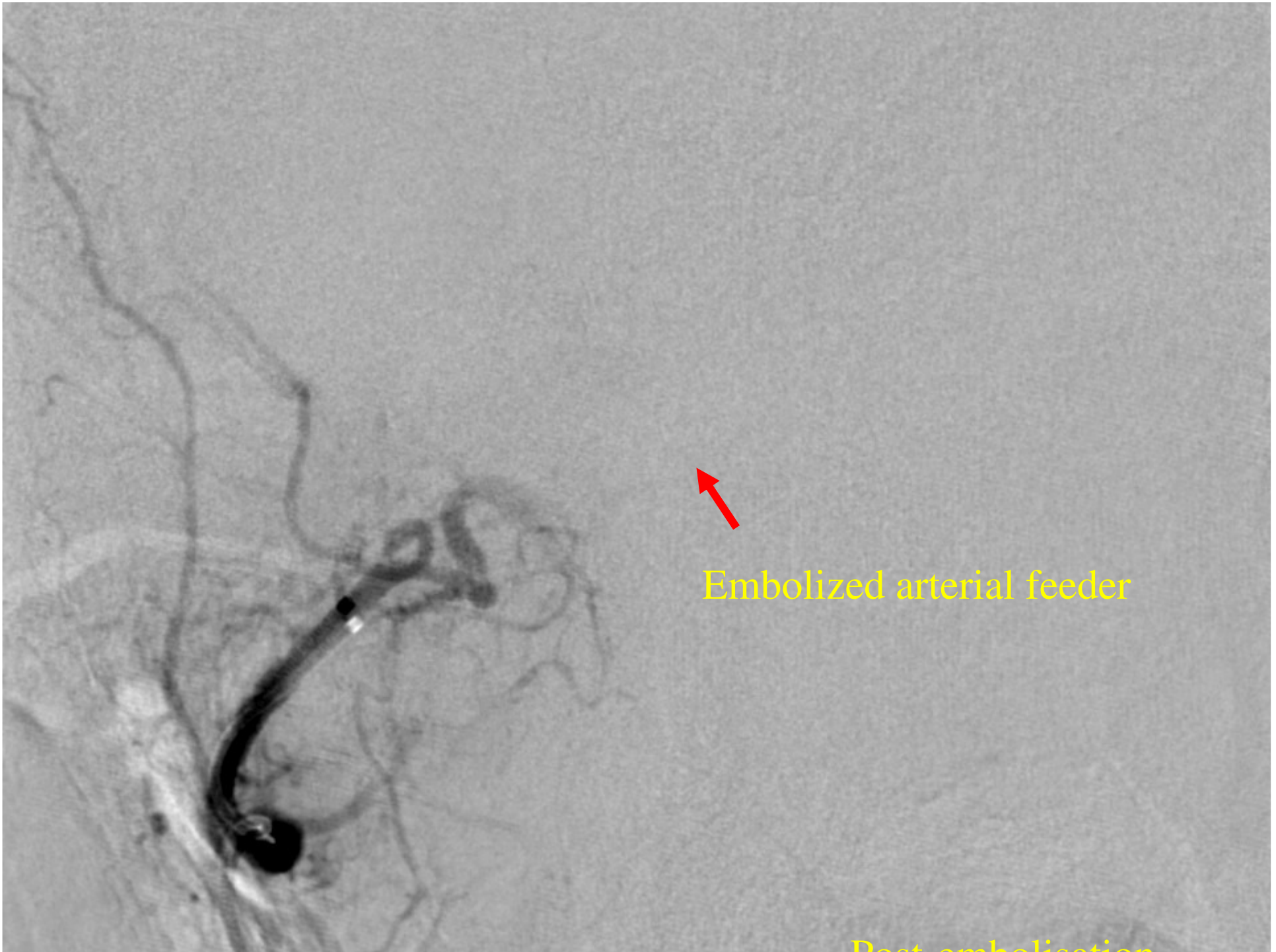[A]

Lateral pre-embolisation  
Left ECA





PA Pre-embolisation Lt ECA

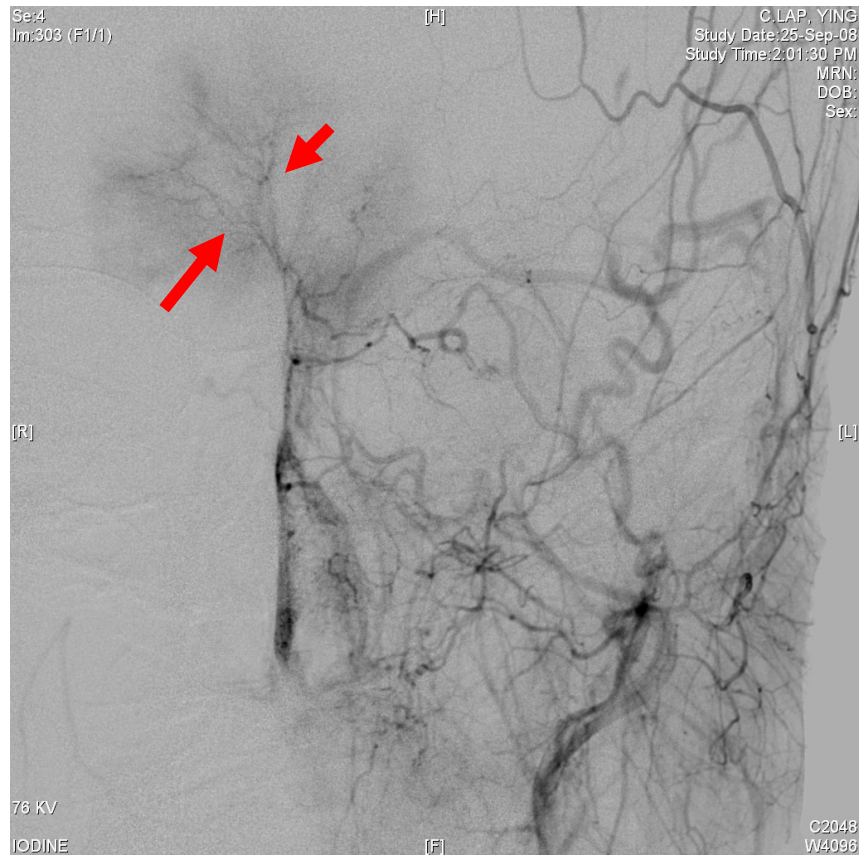


Embolized arterial feeder

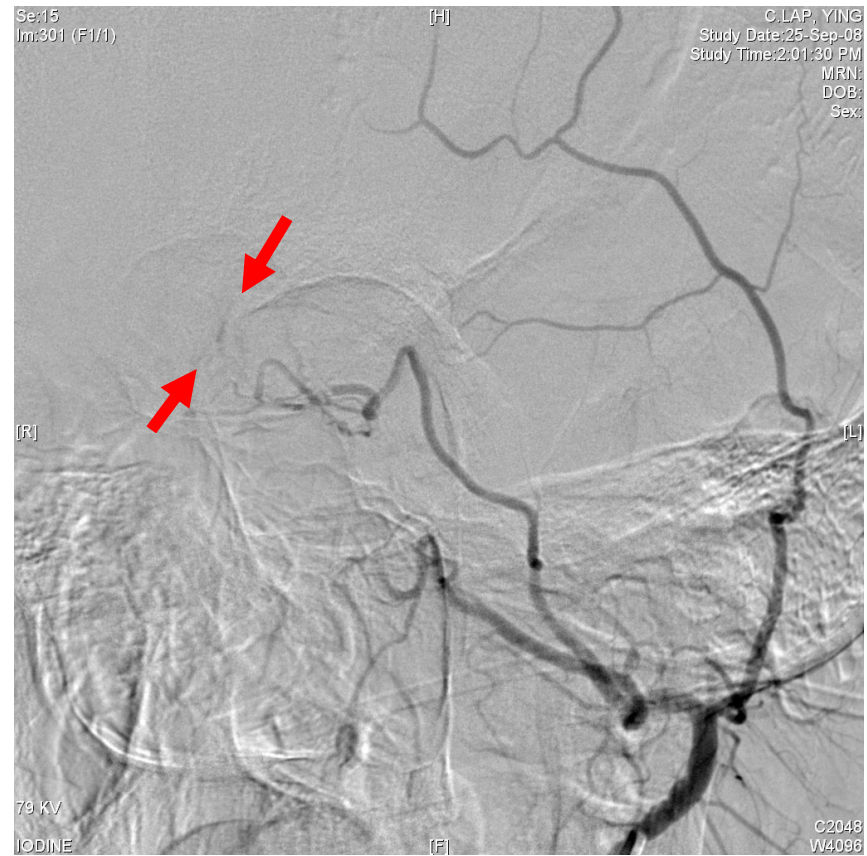
Post-embolization

# Vascular Meningioma

## Pre-operative embolization



Meningioma with prominent feeder

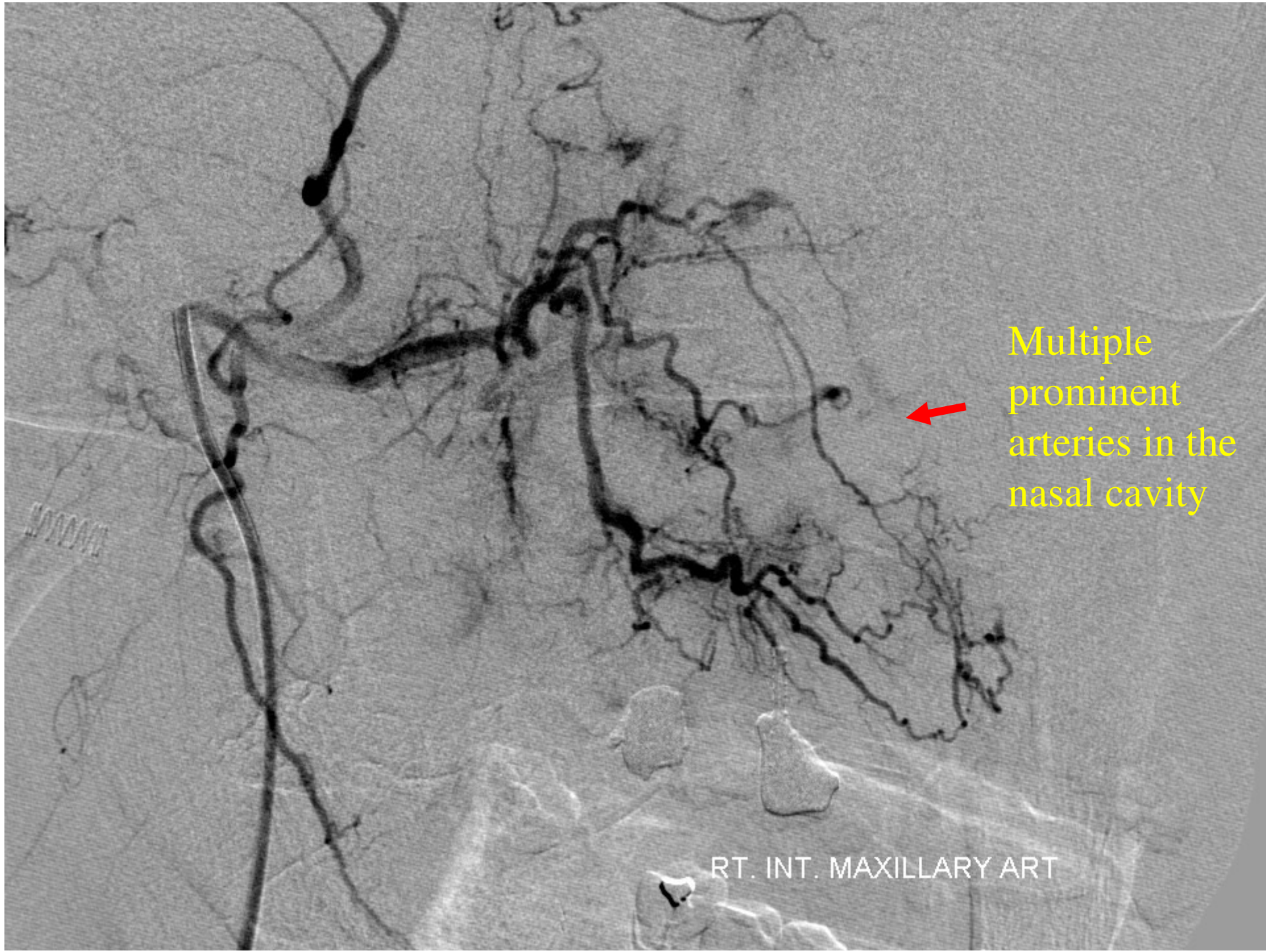


Embolized arterial feeder

# Massive Epistaxis

Often for NPC patient after RT

- 1) Pseudoaneurysm of left ICA, i.e. carotid blow-out.
- 2) Vasculitis or pseudoaneurysm in the nasal cavity



Multiple prominent arteries in the nasal cavity

RT. INT. MAXILLARY ART

Im:302 (F1/1)

Study Date  
Study Time

W.P.O. YUK  
Study Date:07-Nov-05  
Study Time:3:58:23 PM  
MRN:  
DOB:  
Sex:

pseudoaneurysm



pseudoaneurysm



RT. INT. MAXILLARY ART

RT. INT. MAXILLARY ART

Se:11  
Im:302 (F1/1)

[H]

[R]

[L]

[F]

[F]

77 KV

IODINE

C2048  
W4096

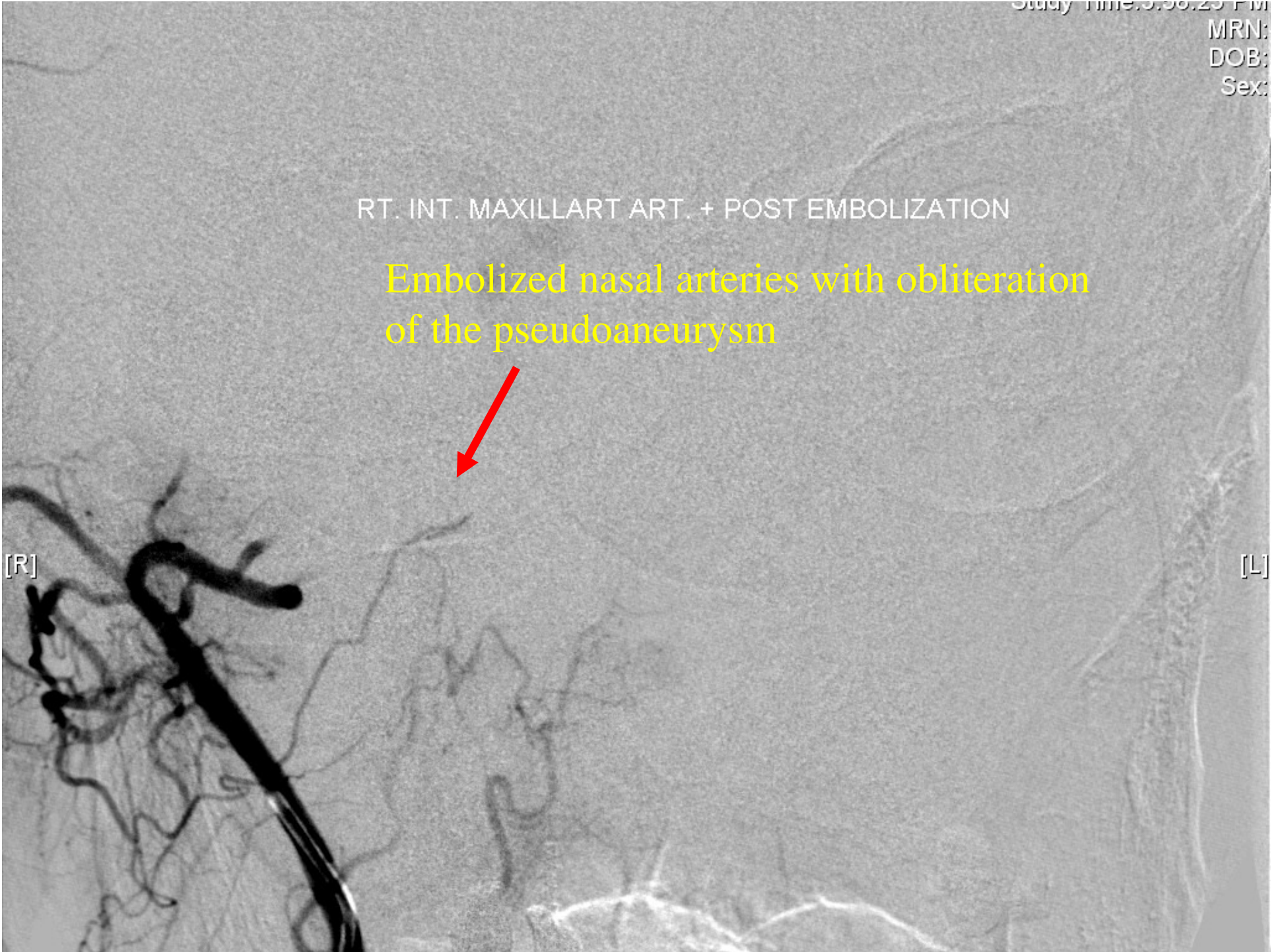
RT. INT. MAXILLART ART. + POST EMBOLIZATION

Embolized nasal arteries with obliteration  
of the pseudoaneurysm



[R]

[L]



# Embolization of renal artery Aneurysm

Se: 453

3D  
Im: 2

Ex: 13913

Se: 4 +c

Volume Rendering No cut

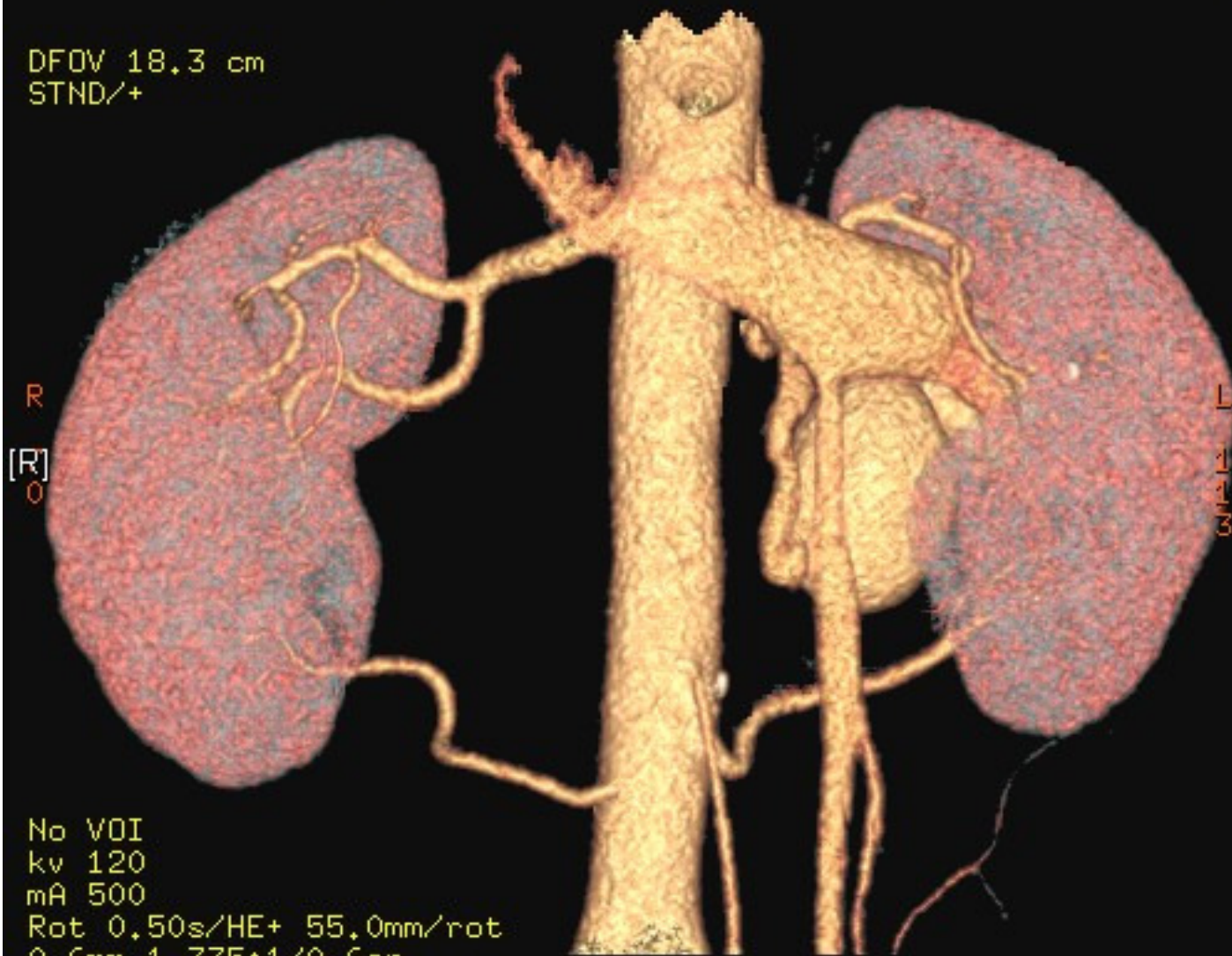
[H] HONG KONG SAM

I 56

Study Time: 8:47:30 AM

Oct 20 2007

DFOV 18.3 cm  
STND/+



R  
O

L  
O

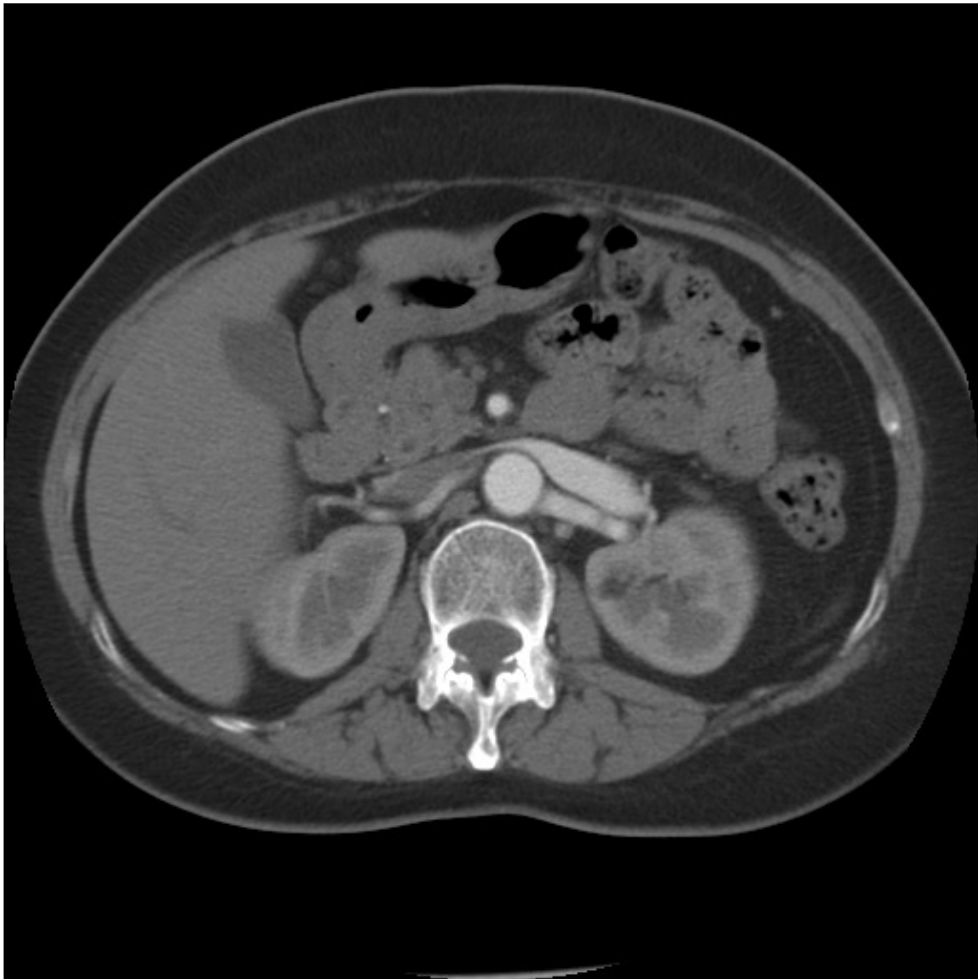
No VOI  
kv 120  
mA 500  
Rot 0.50s/HE+ 55.0mm/rot  
0.6mm 1.375:1/0.6sp  
Tilt: 0.0  
08:59:54 AM  
W = 1993 L = 480

I 239

[F]

C89

W197



Lumen Stripe Length: 24.5 cm      HONG KONG SANATORIUM HO  
LAM, HI  
F 55 E  
Oct 2

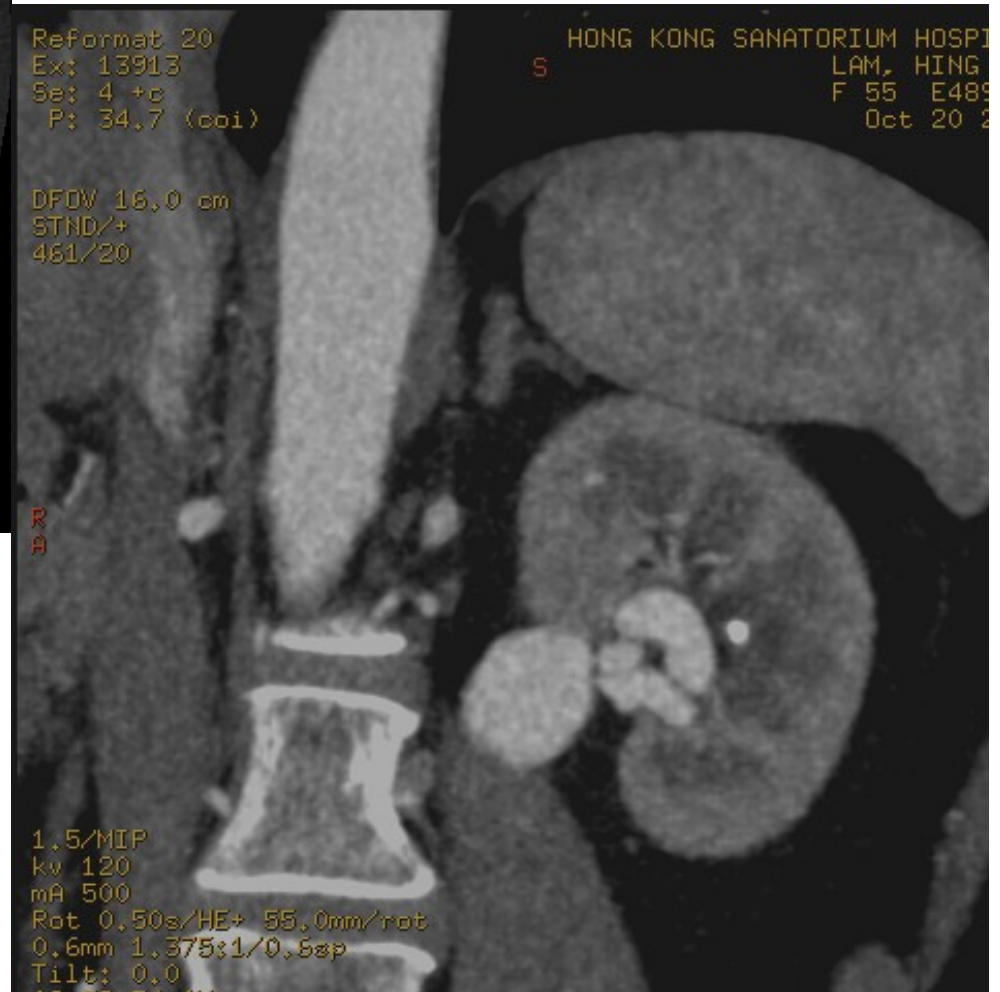
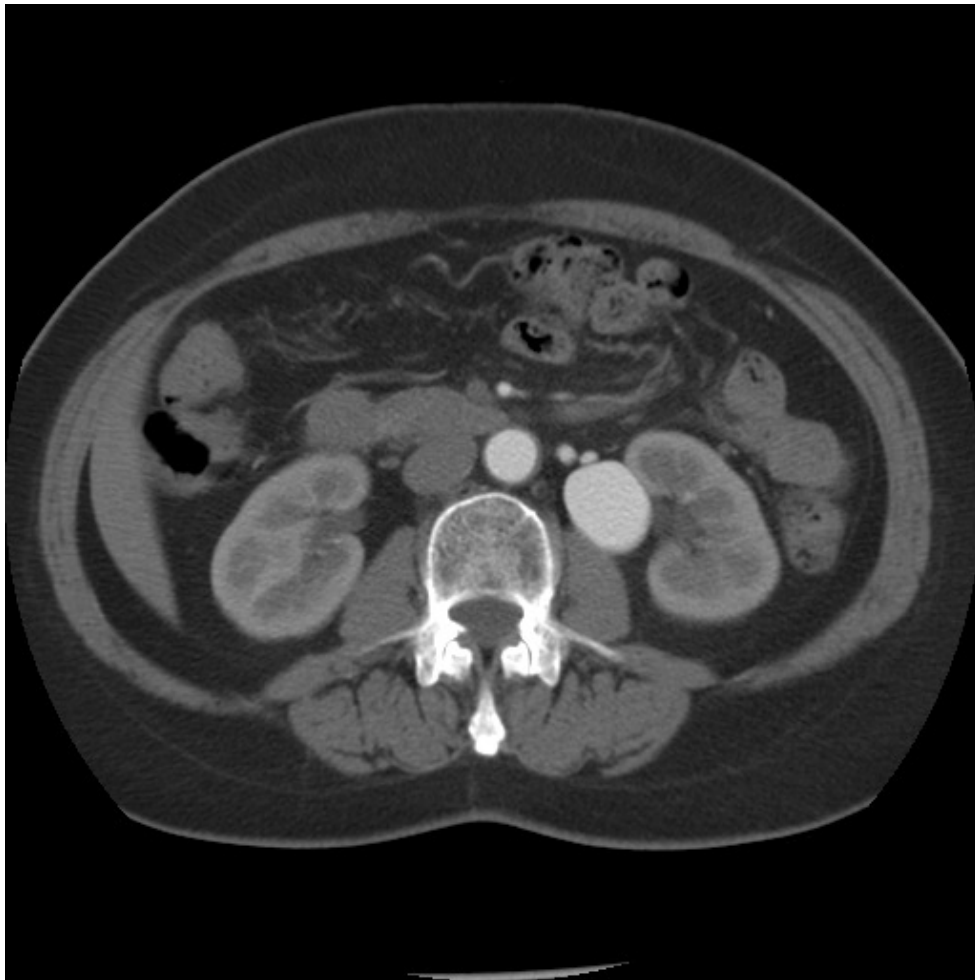Angle: 125.0° Rfmt  
LP: 242.5

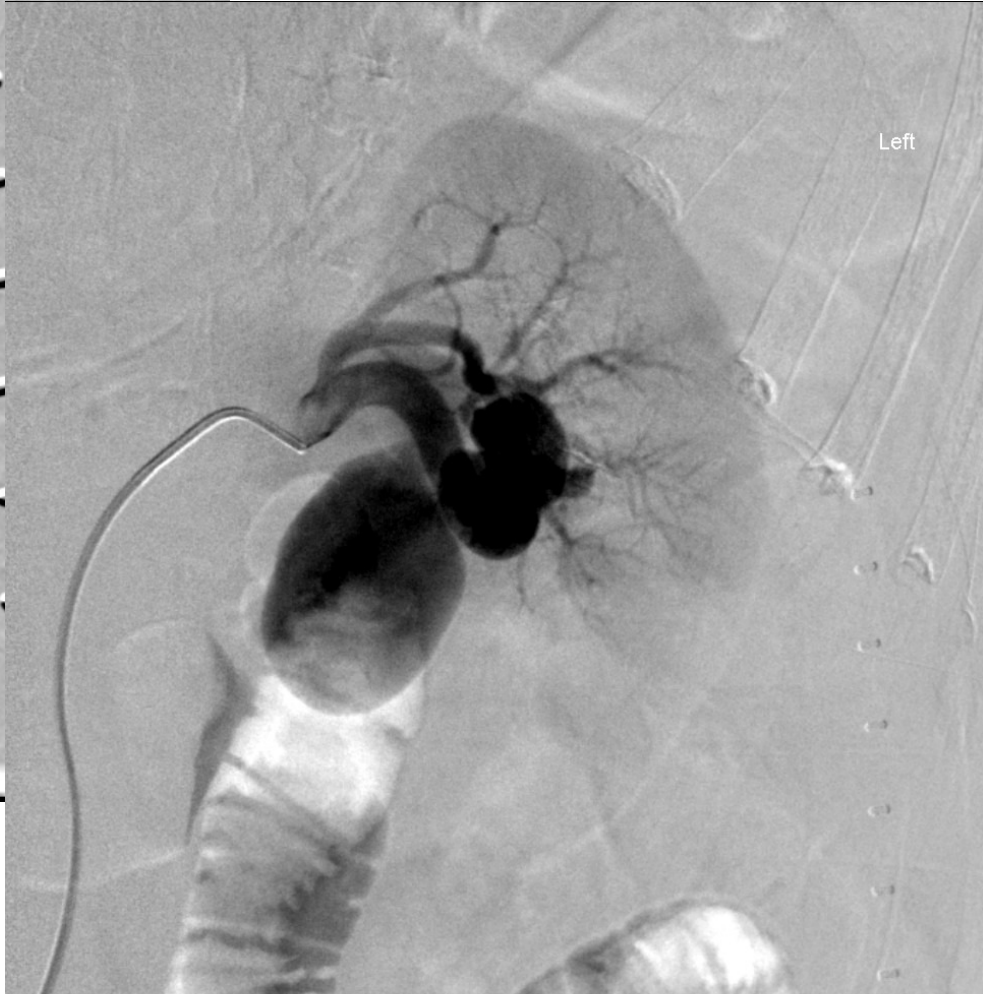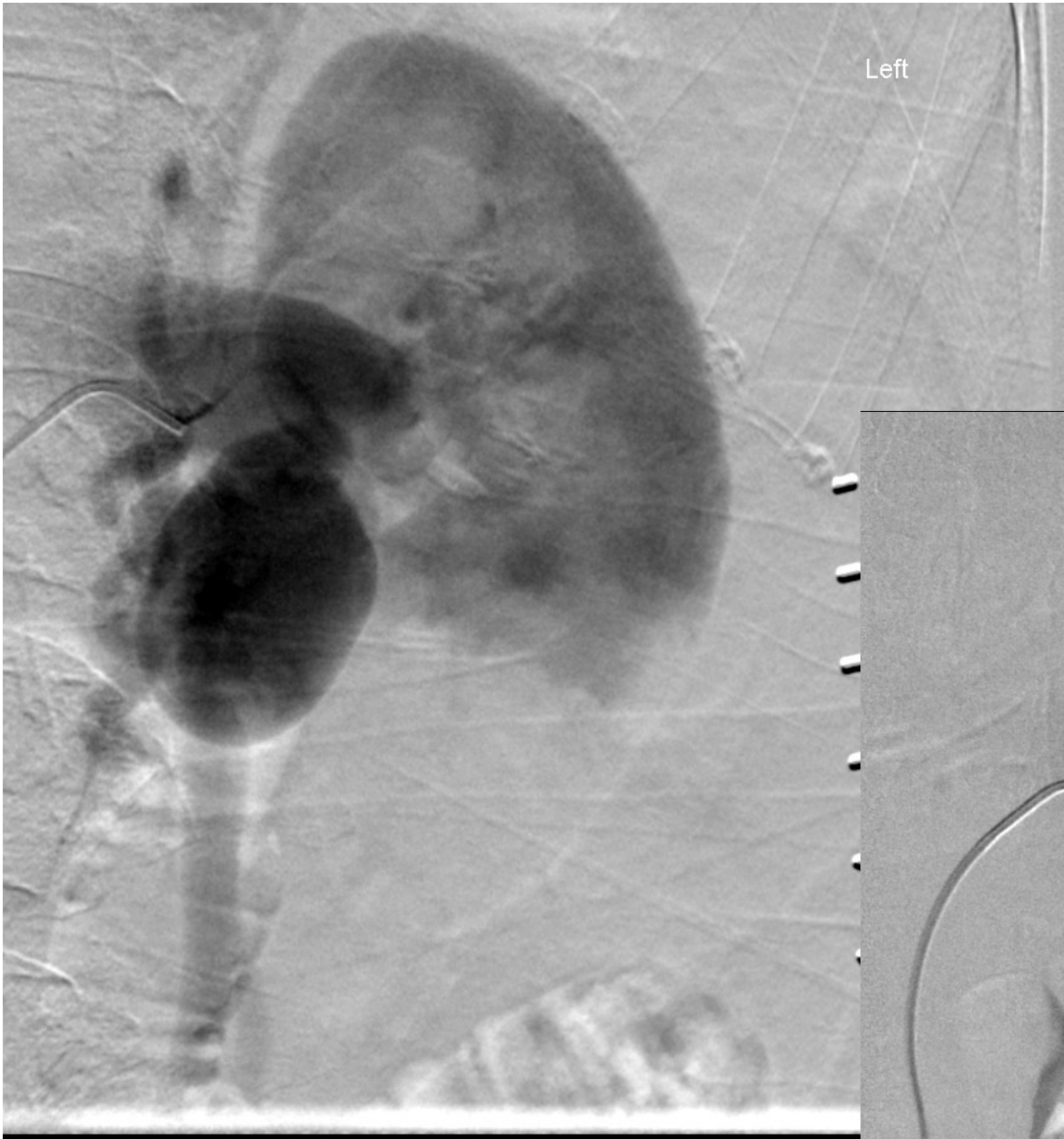Width: 4.0 cm

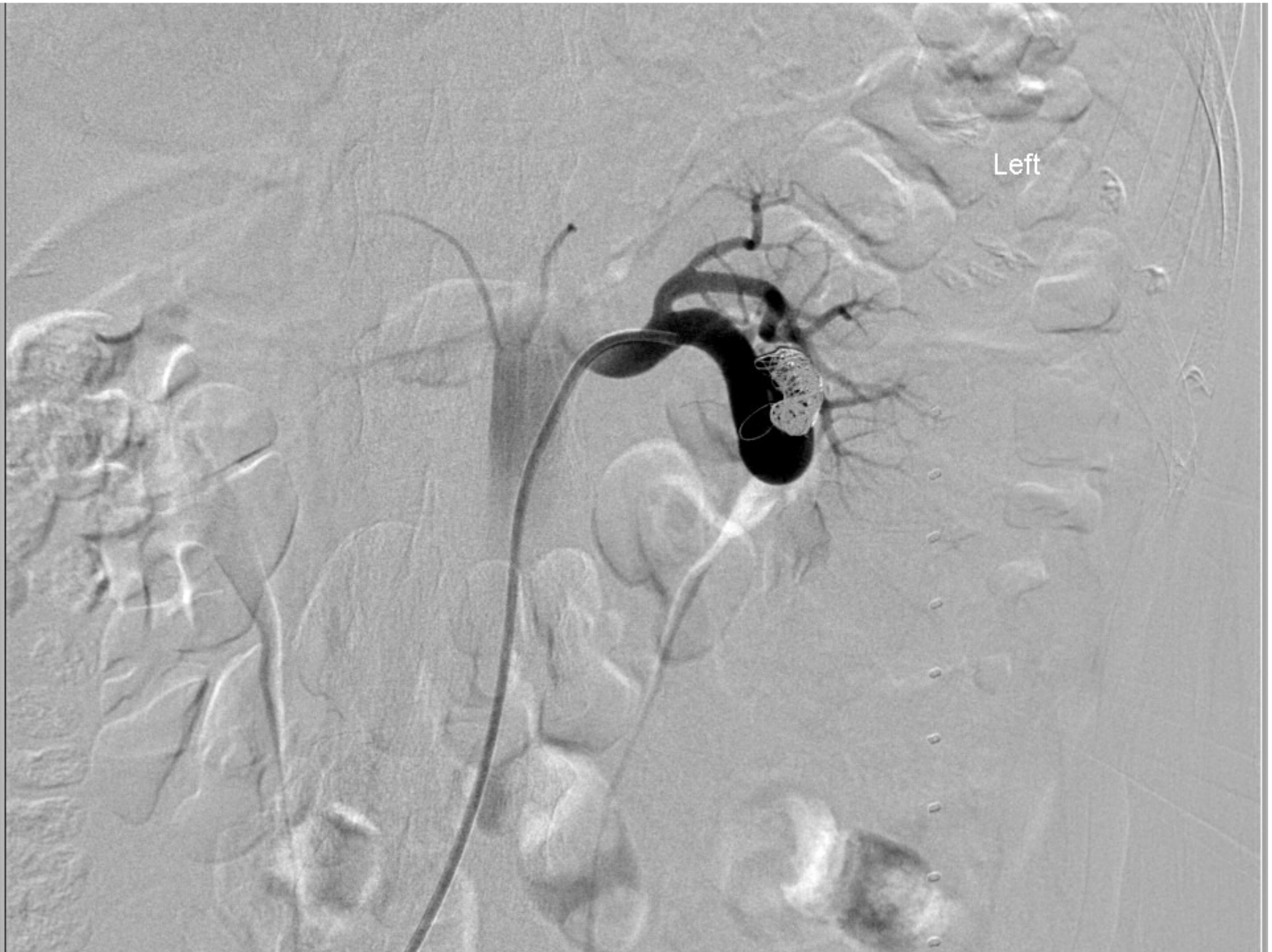Section

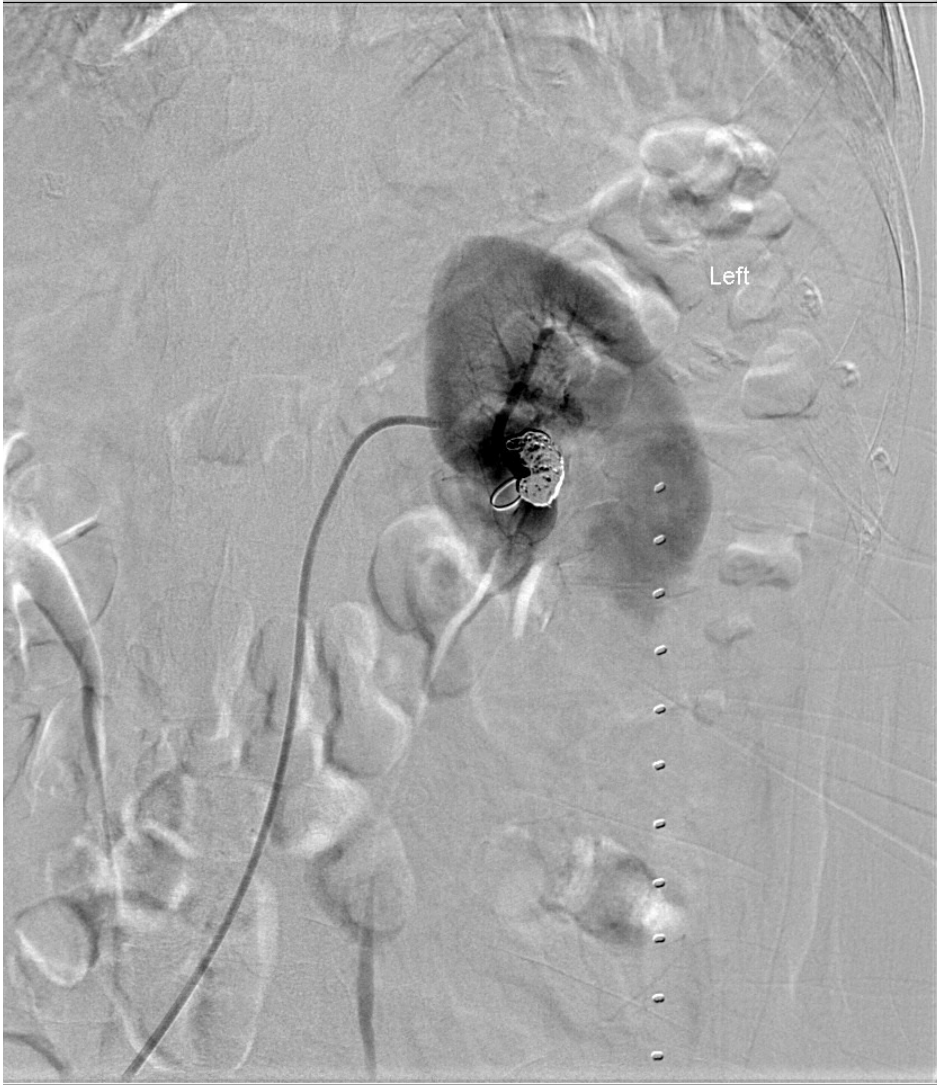
kv 120  
mA 500  
Rot 0.50s/HE+ 55.0mm/rot  
0.6mm 1.375:1/0.6sp  
Tilt: 0.0  
08:59:54 AM  
W = 997 L = 246

Lumen view is NOT intended for dia

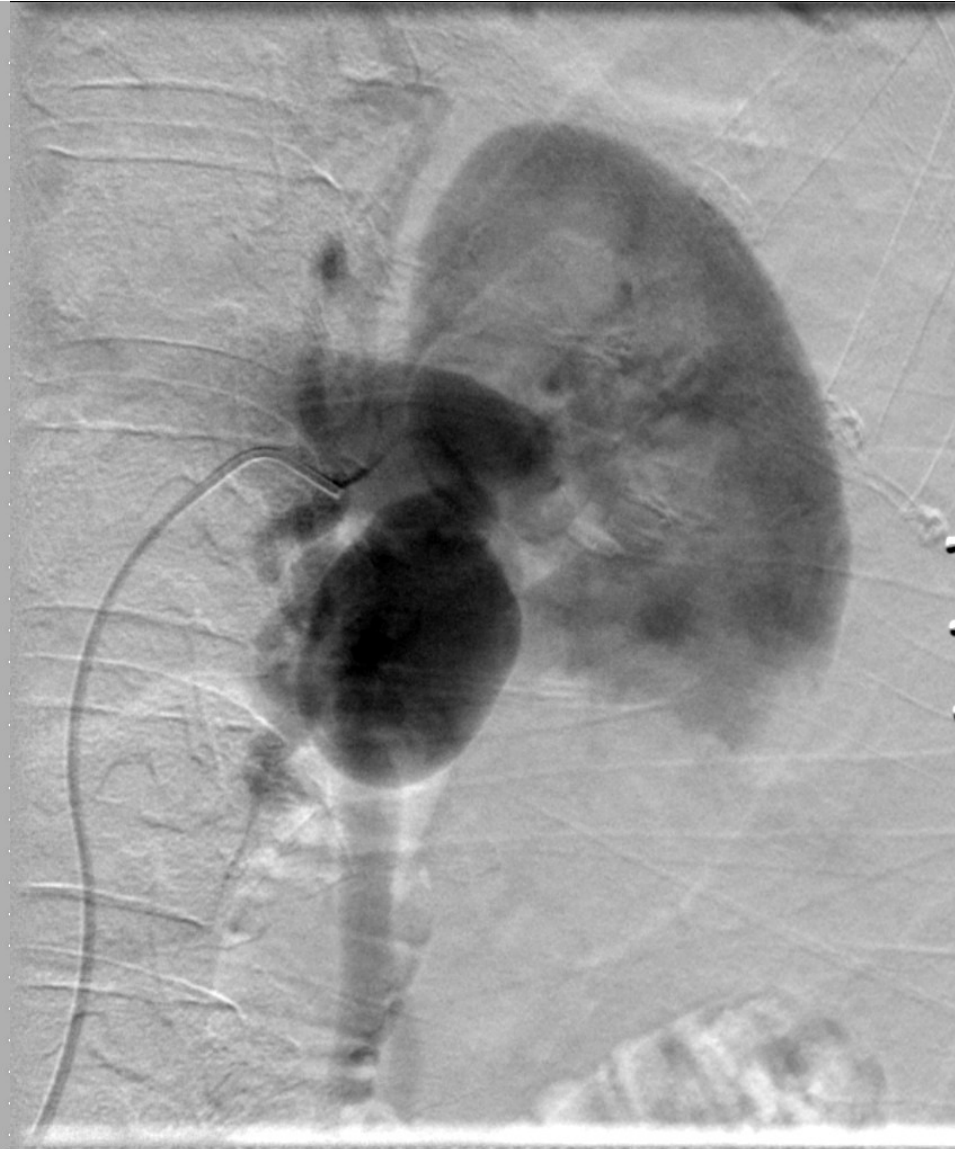







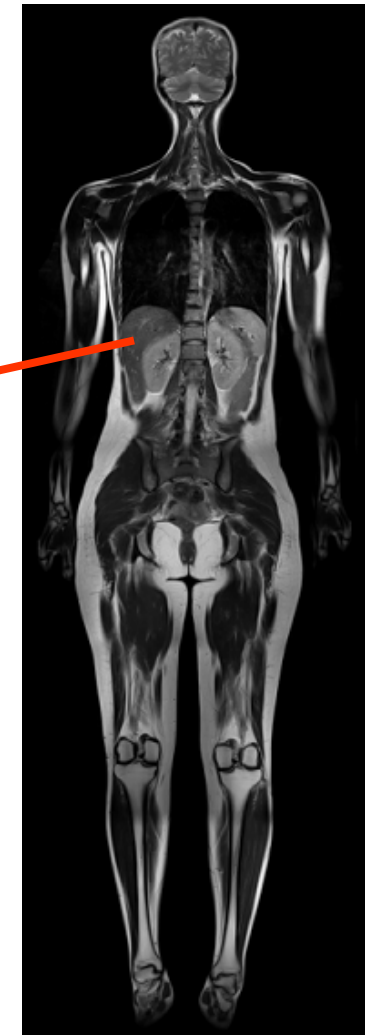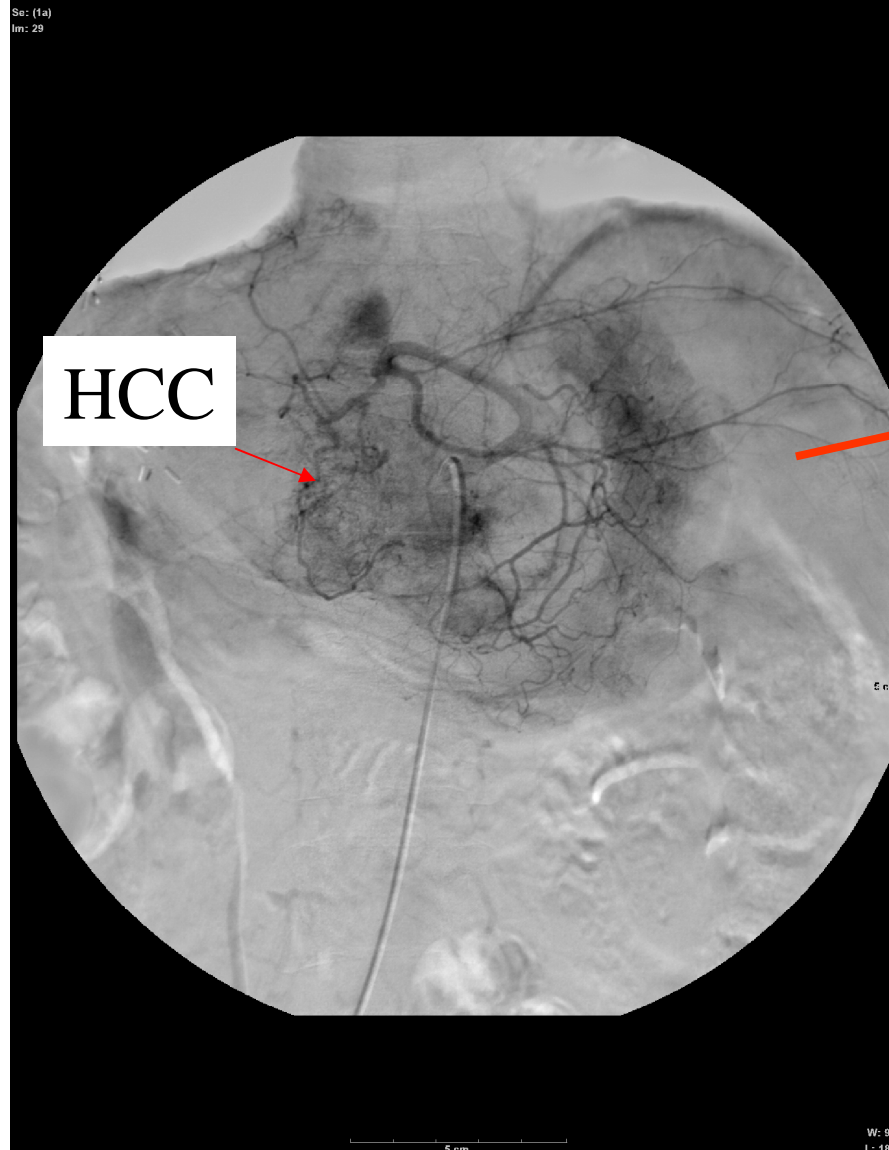
Post-GDC coil embolization



Pre-GDC coil embolization

- Liver Tumour Treatment

# Pre-treatment Hepatic Angiogram

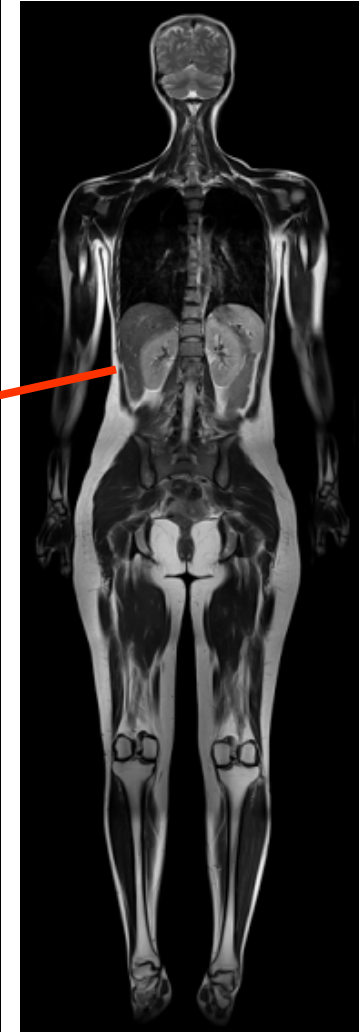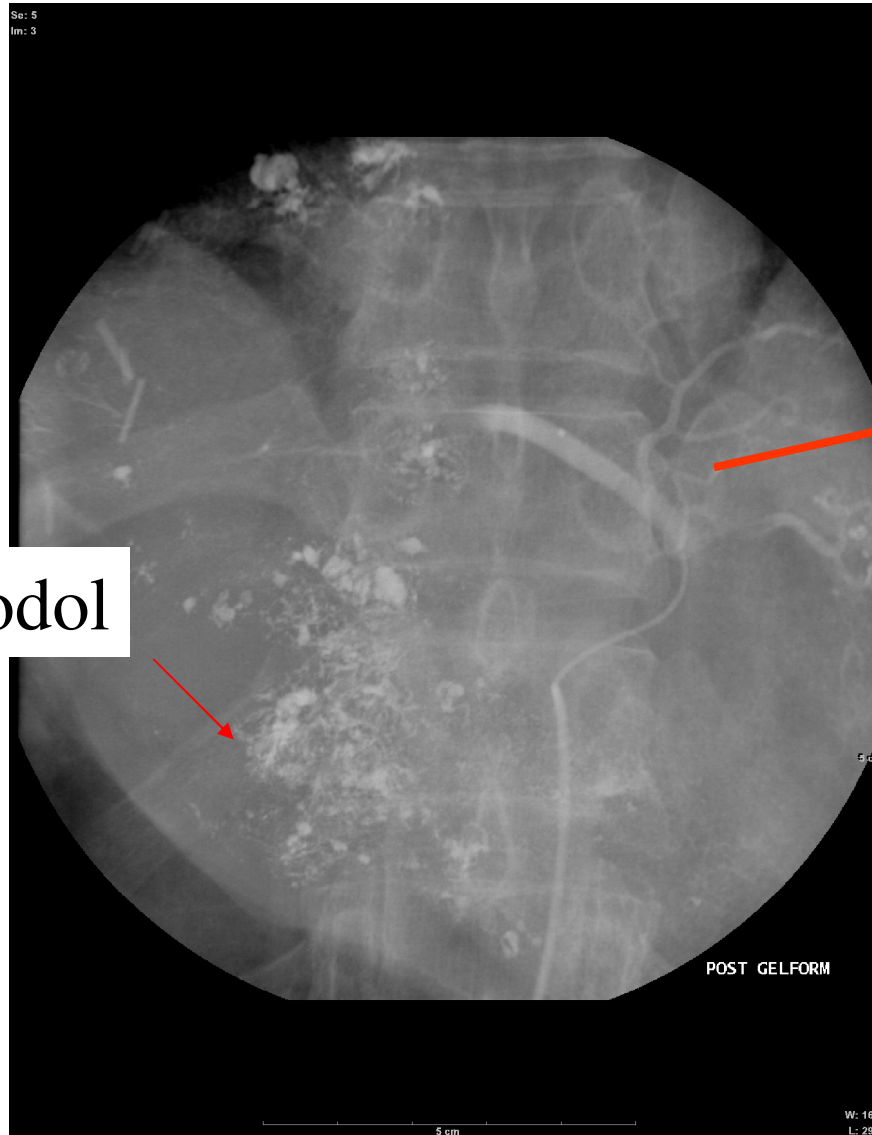


# Transarterial Chemo-embolization

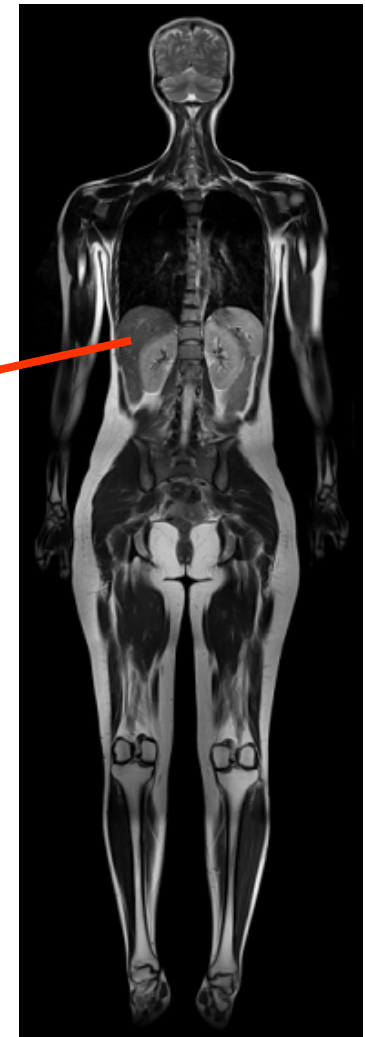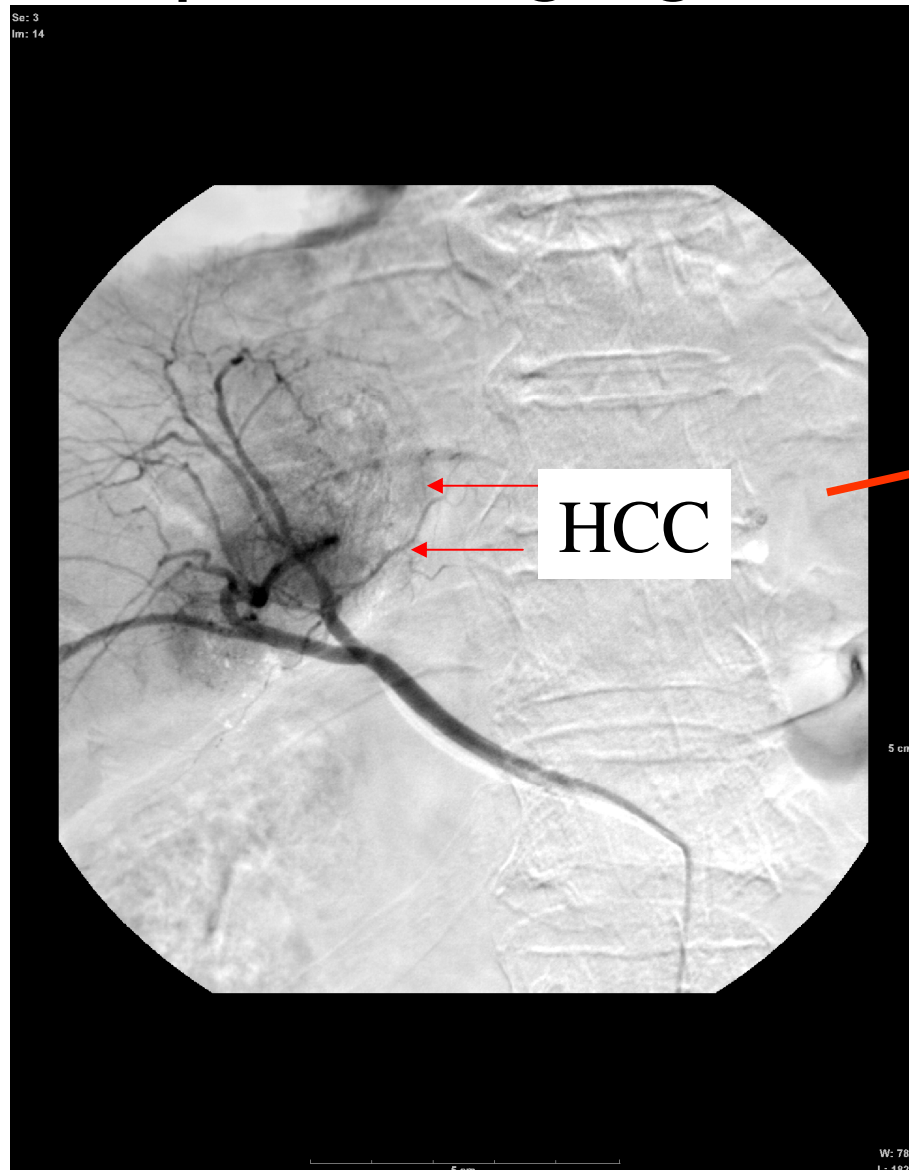
TACE

經動脈(化療)栓塞

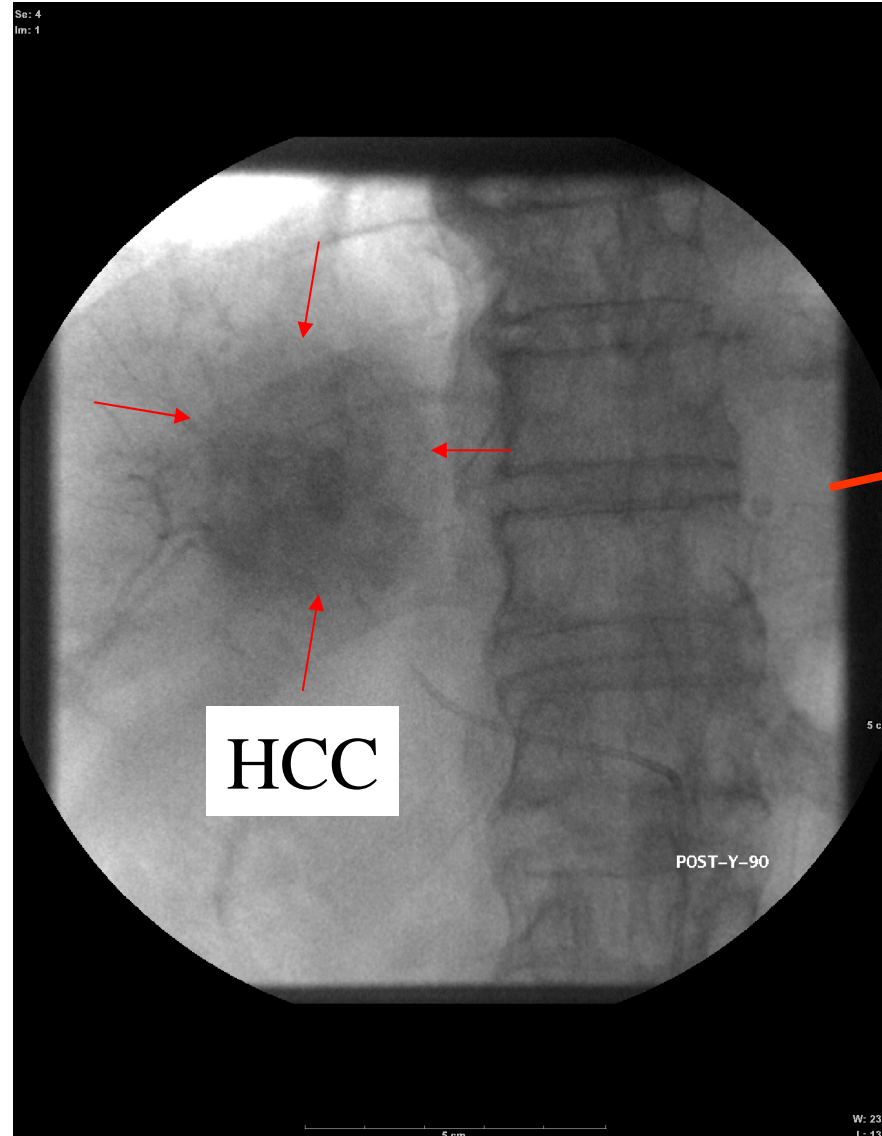
Lipiodol

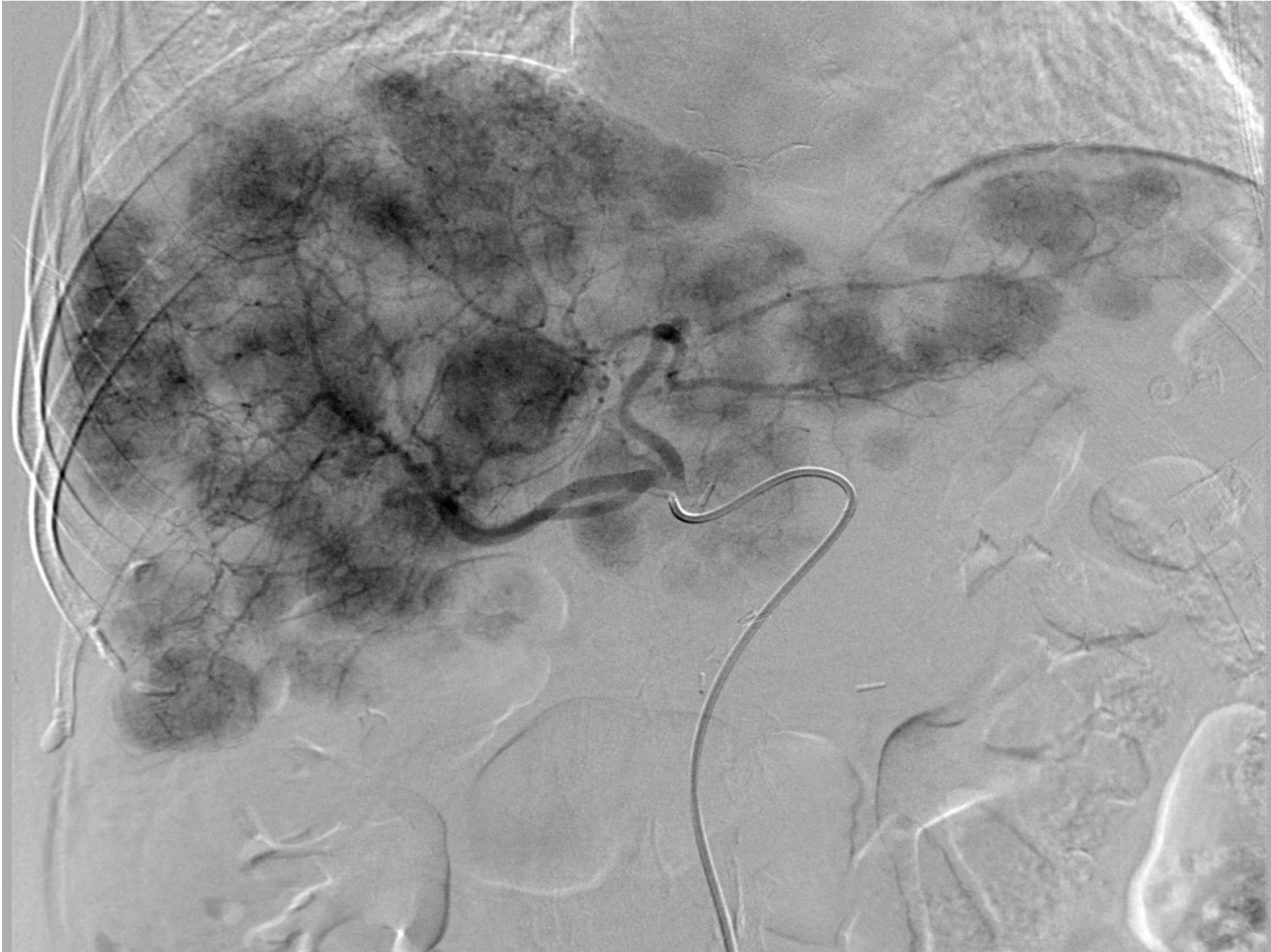


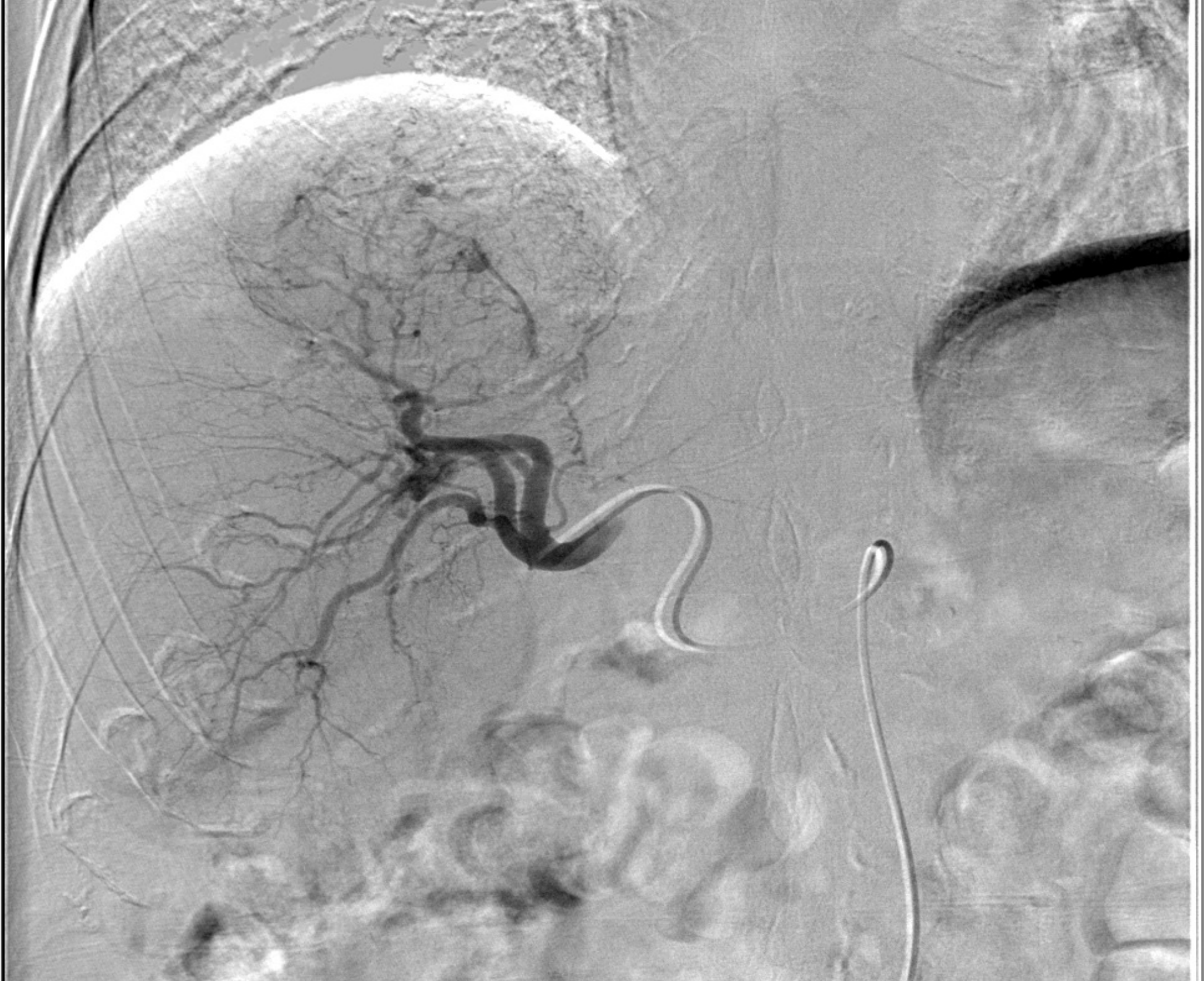# Pre-treatment Hepatic Angiogram

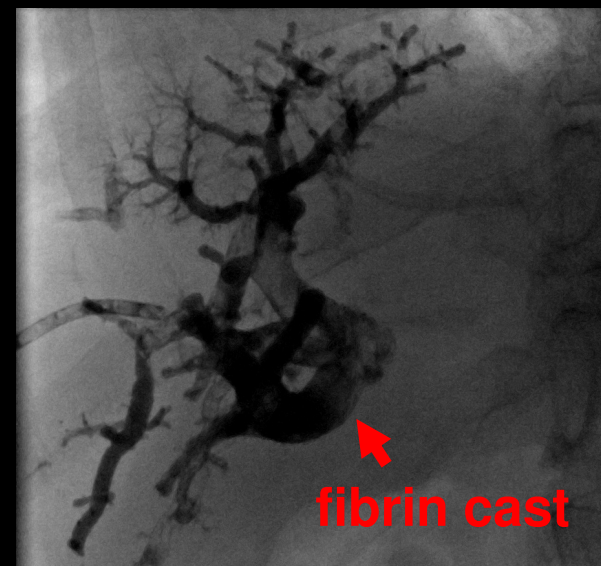
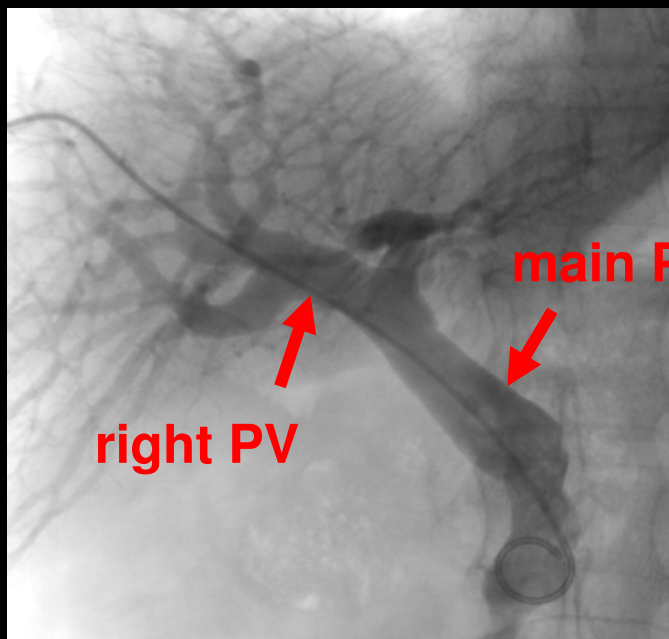
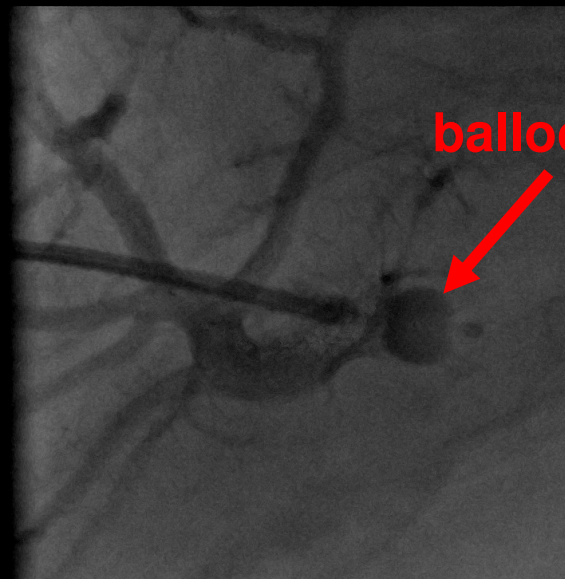
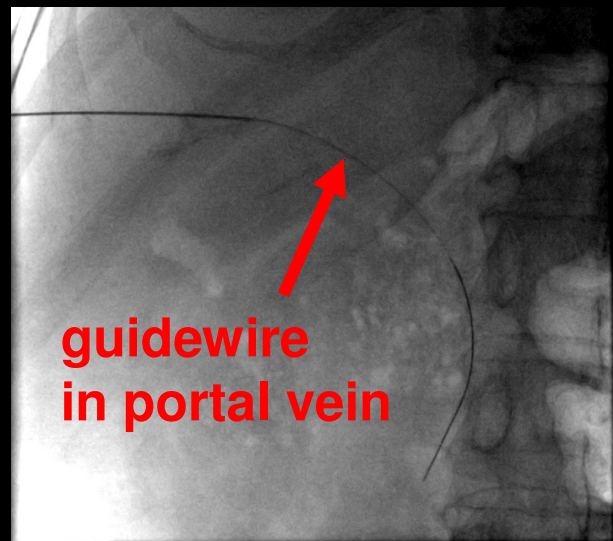


# Yttrium-90 Selective Internal Radiation Therapy





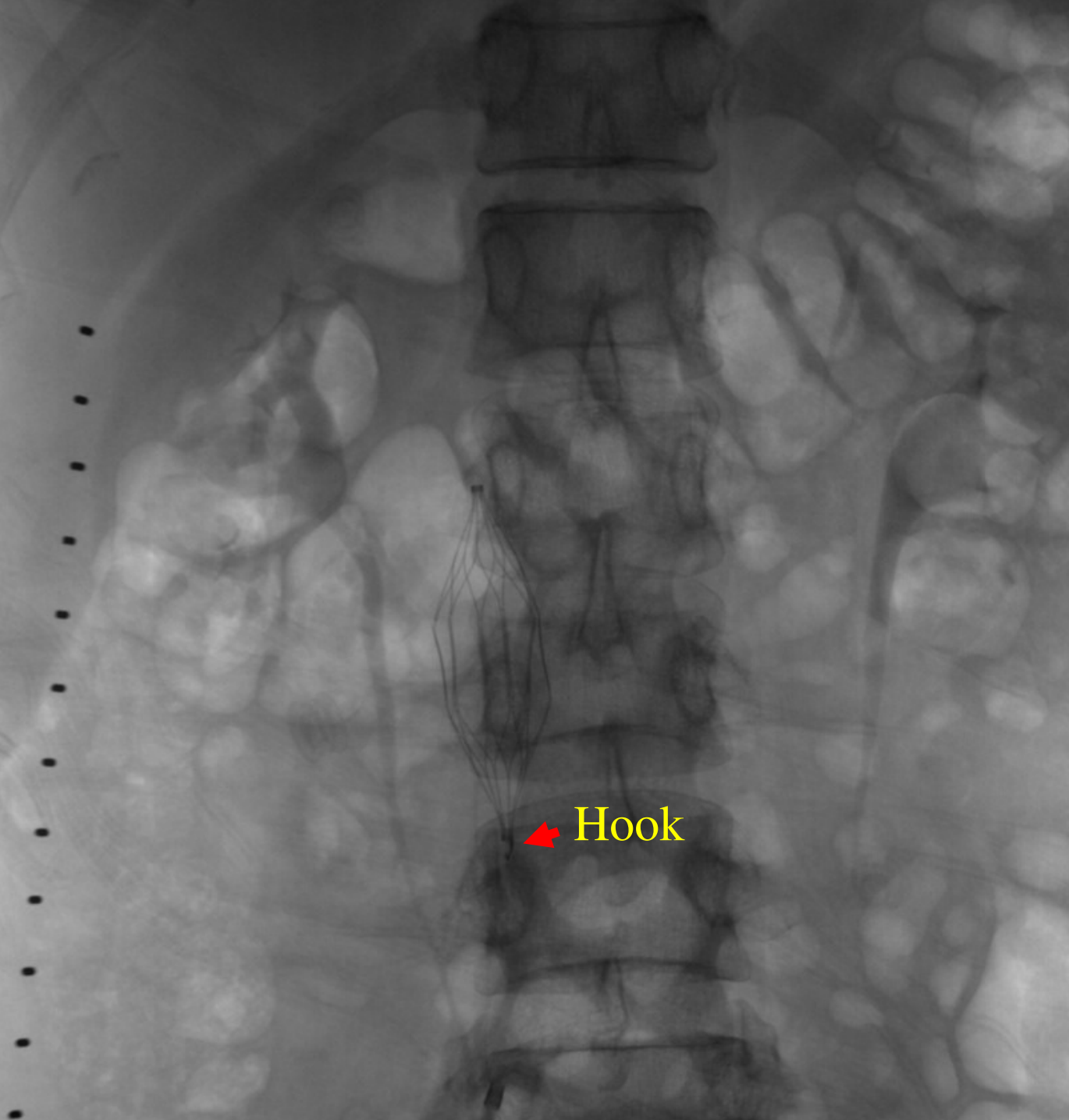




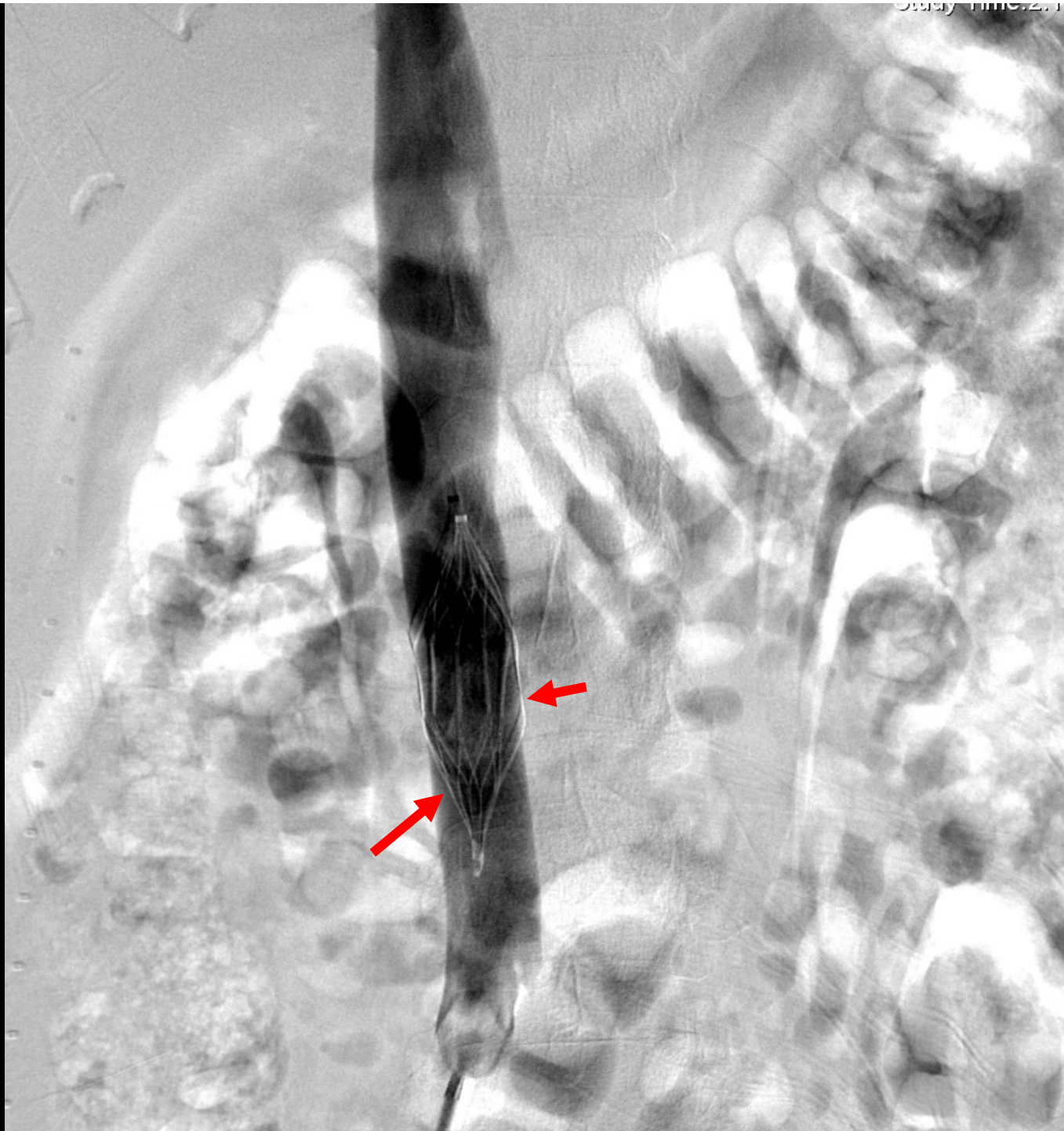# IVC Filter

## 下腔静脉滤器

- Patient with tumour and also DVT – Pre-operative measure
- Renal tumour with renal vein extension- pre-operative IVC filter and then removed.



Hook



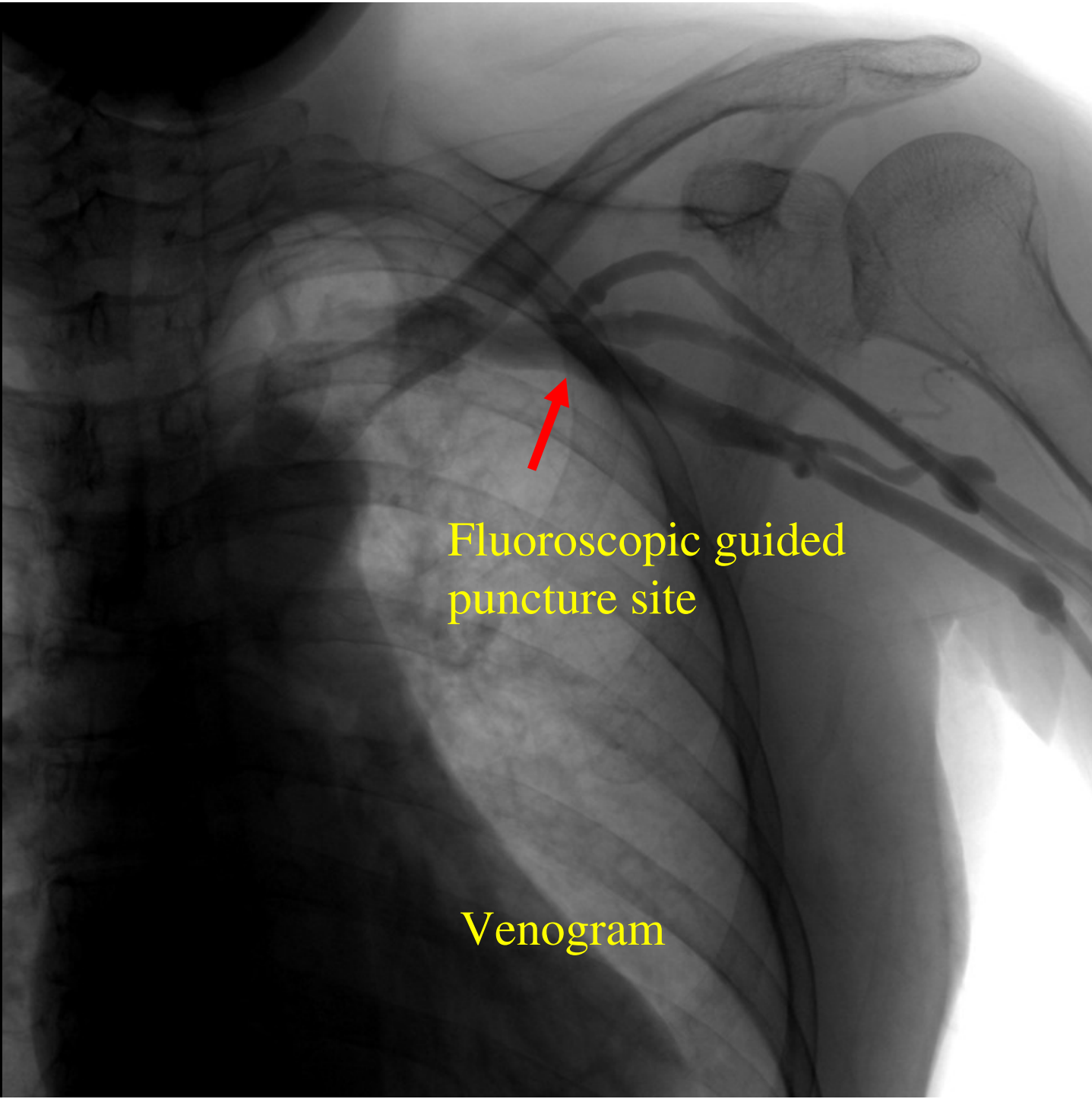
# Port A Catheter Placement

- For Chemo-agent injection
- For blood taking

- Procedure:

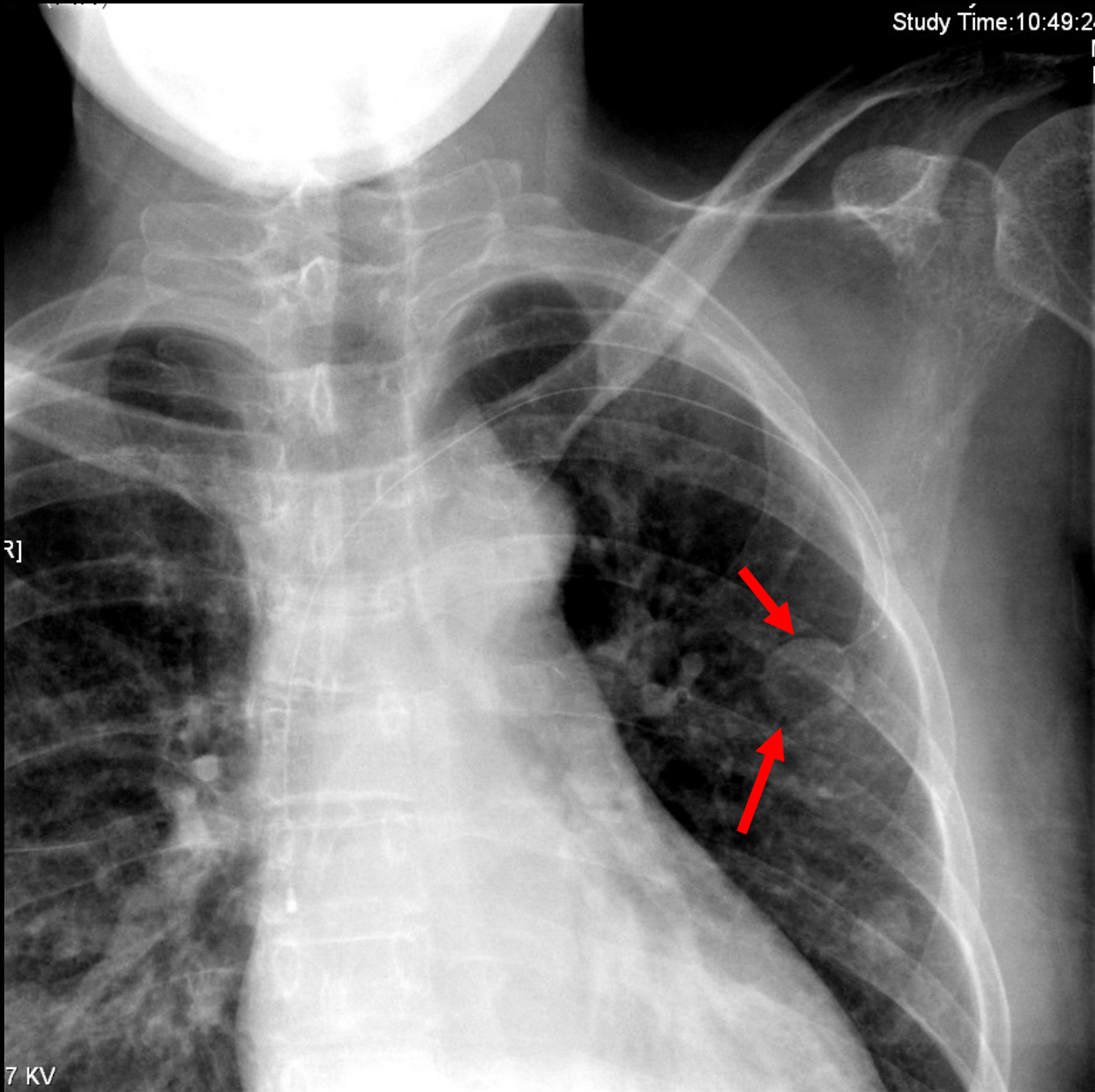
Fluoroscopic or US guided venous puncture and insertion of the catheter

Create a subcutaneous tunnel and then connected the Port to the catheter



Fluoroscopic guided  
puncture site

Venogram

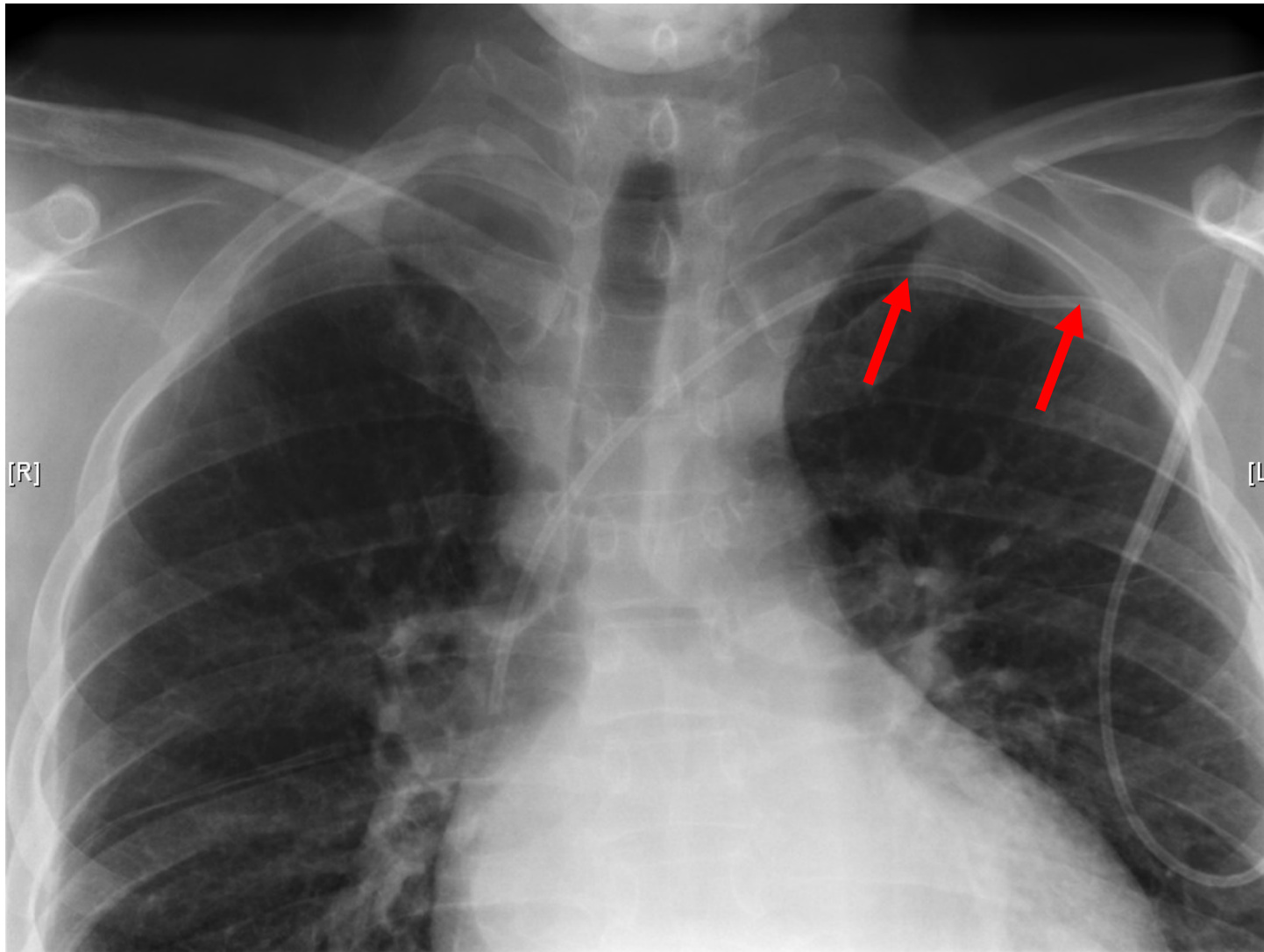


Study Time: 10:49:2

R]

7 KV

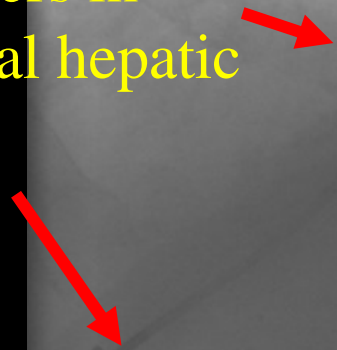
# Hickman Catheter Insertion



# Venous sampling

- Localization of insulinoma– Arterial calcium stimulation
- Adrenal venous sampling
- Inferior Petrous Sinus sampling – Pituitary hormonal secreting tumour

Catheters in  
bilateral hepatic  
veins



Catheter in  
SMA



# Conclusion:

## Interventional Radiology

Interventional Radiologist uses image-guided, minimally-invasive approaches to

- Diagnose
- To give the treatment or pre-operative assistance
- To manage post-treatment or disease-related complications